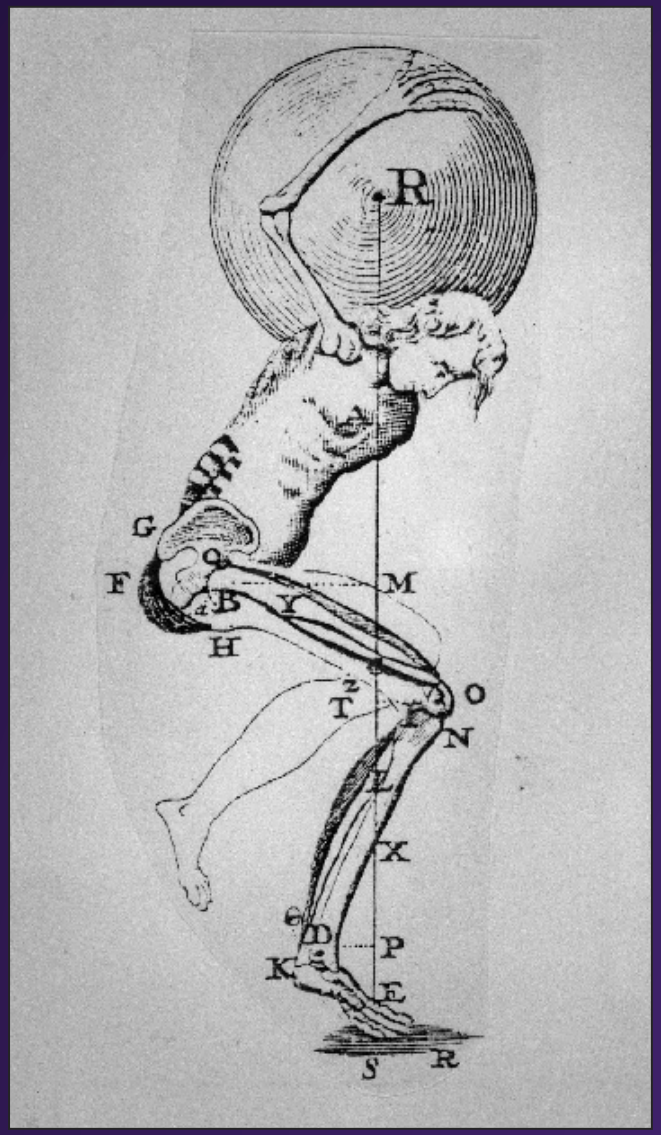

Musculoskeletal Biomechanics

BIOEN 520 | ME 527

Session 5A

Imaging in Biomechanics

Review: Session 4A and 4B

- Kinematics and kinetics from the RGS
- Kinematics highlights
  - Position vectors and rotation matrices
  - Marker-based coordinate systems
  - Anatomic vs. technical coordinate systems
  - Description of rigid body kinematics
- Kinematics and kinetics of gait analysis
- Mini-Lab #2: Grant writing
- Final project
- Homework 1
- Tour and lab at ABL

Session 5A and 5B Overview…

- Review sessions 4A and 4B
- Imaging in Biomechanics
- Biplane fluoroscopy
- Histology and Biochemistry

Imaging in Biomechanics

- Bone scans
- Bone density scans
- Others:
  - fMRI
  - PET scan

Bone scans

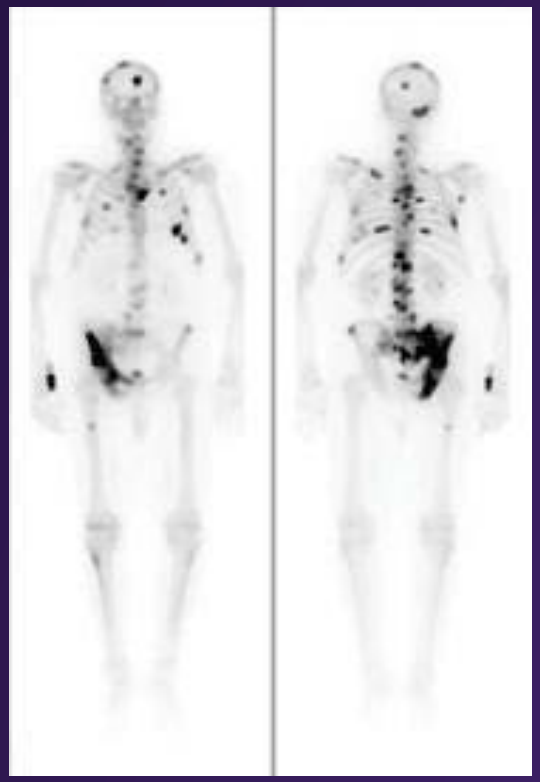

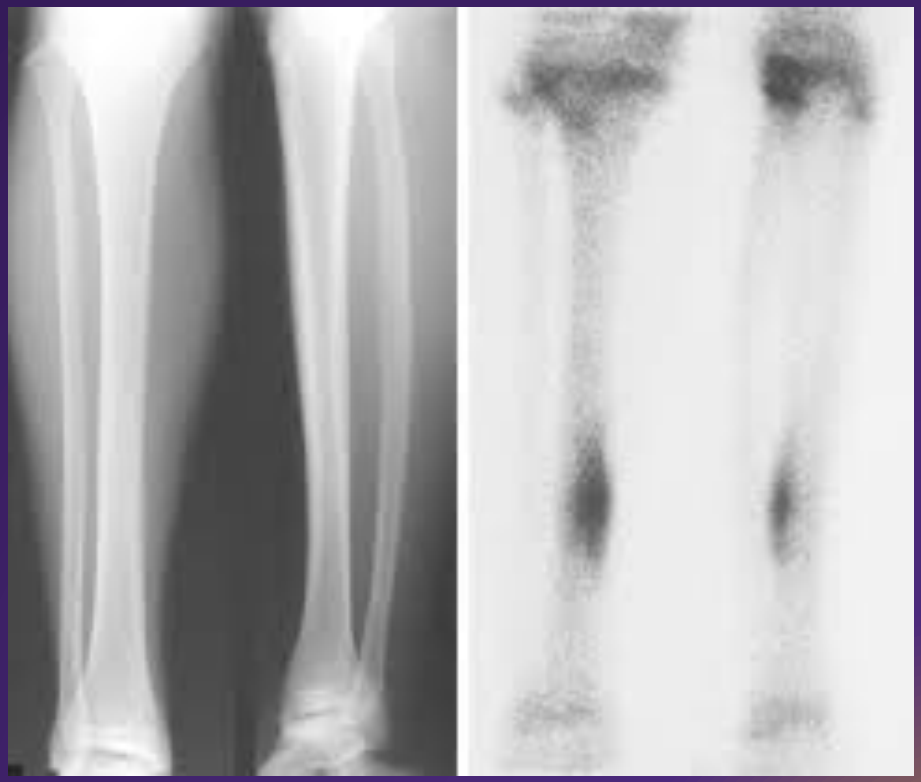

Very small amount of radioactive dye to help diagnose problems with your bone metabolism – abnormal bone growth – due to fracture, infection, cancer, arthritis, trauma, etc.

Bone density scans

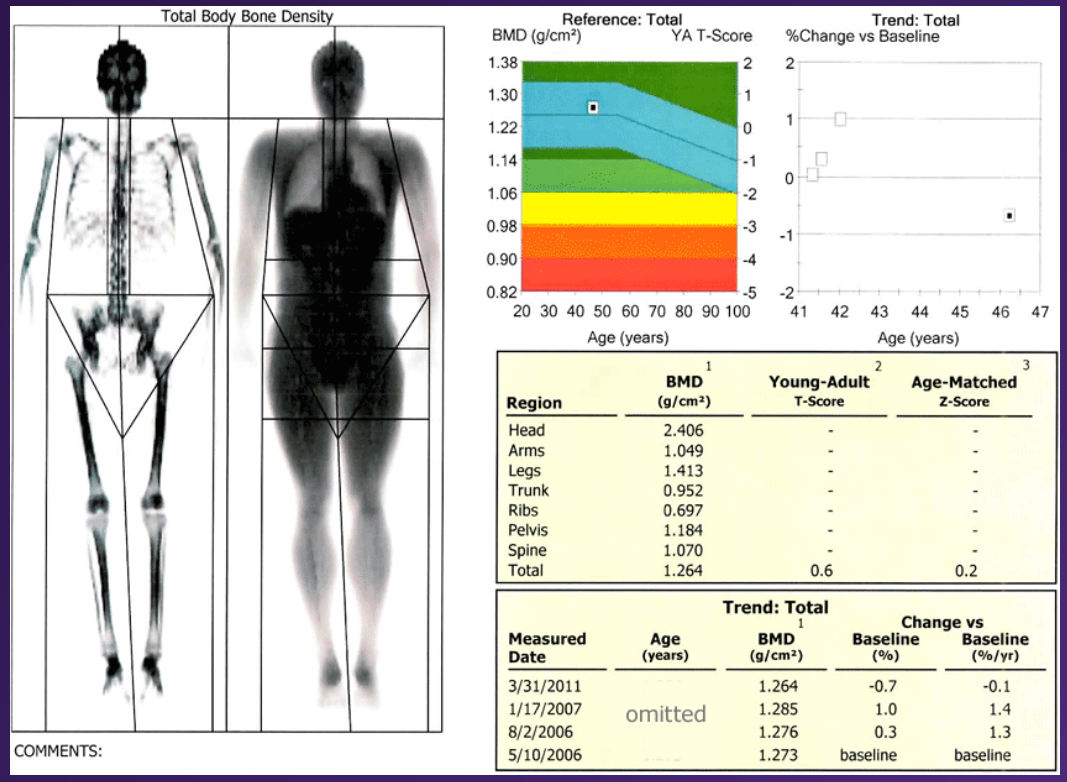

Region	BMD (g/cm²) [1]	Young-Adult T-Score [2]	Age-Matched Z-Score [3]
Head	2.406	-	-
Arms	1.049	-	-
Legs	1.413	-	-
Trunk	0.952	-	-
Ribs	0.697	-	-
Pelvis	1.184	-	-
Spine	1.070	-	-
Total	1.264	0.6	0.2

Trend: Total

Measured Date	Age (years)	BMD (g/cm²) [1]	Change vs Baseline (%)	Change vs Baseline (%/yr)
3/31/2011	omitted	1.264	-0.7	-0.1
1/17/2007		1.285	1.0	1.4
8/2/2006		1.276	0.3	1.3
5/10/2006		1.273	baseline	baseline

DEXA (Dual X-ray Absorptiometry Test)
Scan lumbar vertebrae, upper femur, forearm, wrist
Information used to generated a T-score
-1.0 = healthy; -1.0 to -2.5 = at risk; < -2.5 osteoporotic

FOUR MODALITIES

The Matrix

	CT	Ultrasound	X-ray	MRI
$: buy ($M)/ use ($1000)	1-2/0.3-0.5	0.1-0.3/0.1-0.3	0.5-1.5/0.1-0.5	2-3/0.3-0.5
Risks	X-ray effects	None	X-ray effects	None
Temporal resolution	Low (1 minute)	High (to 30 msec)	High (to 10 msec)	Low (3D), 1-2 sec (2D), gating
Spatial resolution	Medium (to 500 microns)	Medium to high (to 100 microns)	High (to 150 microns)	Medium (0.5-1 mm 3D)
What is seen	Bones, soft tissues, fat	Soft tissue boundaries	Bones, markers	Everything
2D/3D	3D	2D (slow 3D)	2D (projection)	2D or 3D
Limitations	Poor soft tissue discrimination	Soft tissue only, blocked by bone	Bones only	Physically constrained
Applications	3D morphology, esp. for bones	Soft tissue motion, elastography	Bone/marker motion, dynamic studies, weight-bearing	3D morphology, muscle use and structure, quasistatic studies, elastography

-X Ray and Fluoroscopy (1895)

-Ultrasound (1917)

-MRI (1946)

-Computerized Tomography (1970s) x-ray based

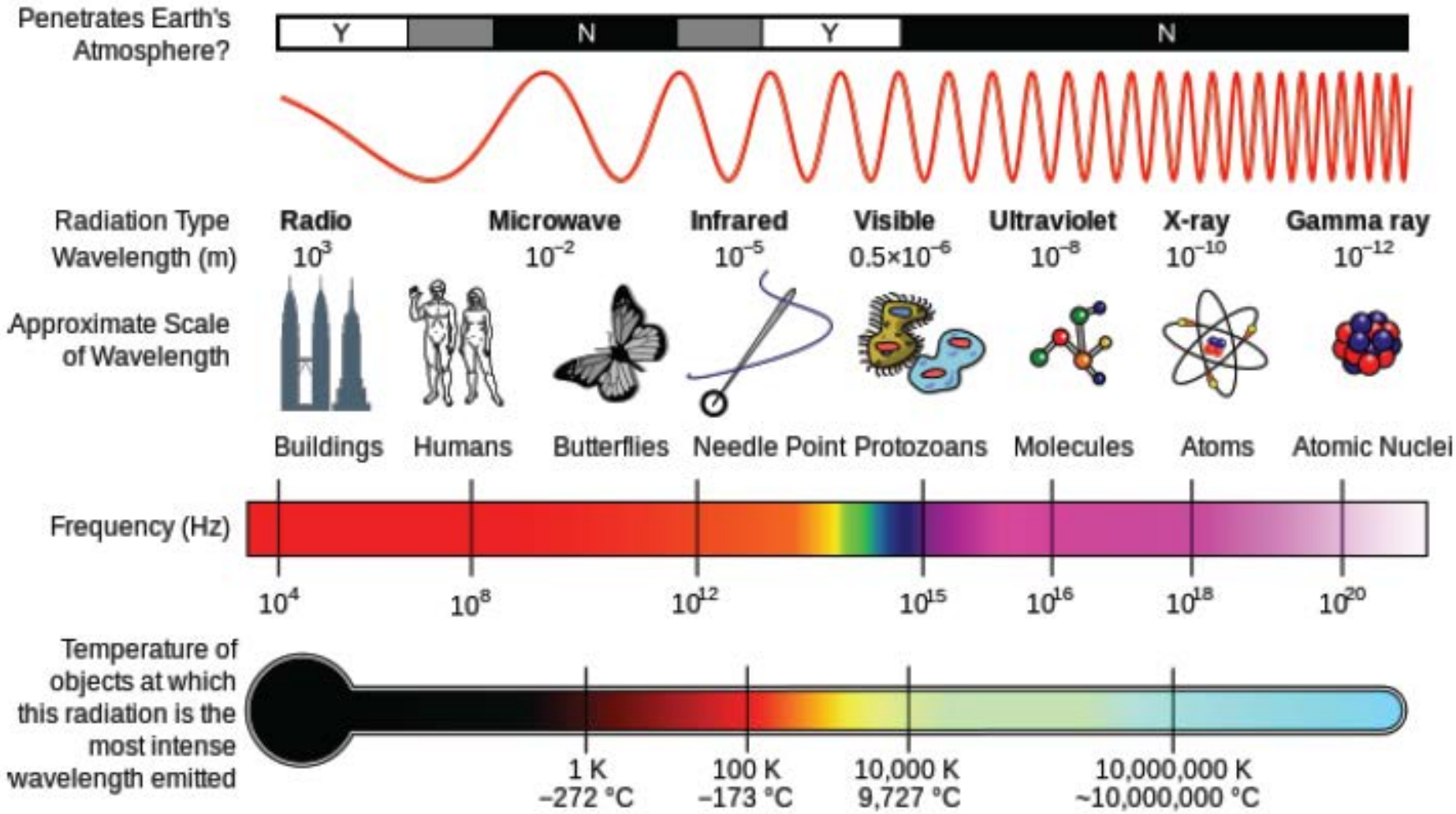

X-ray dosage

- Many factors to consider – spectrum, directions, sensitivity of body parts, age, rate…
- Lower extremities least radiosensitive
- Additional risk of cancer = .004%/mSv
- Average background dose in US = 3.1 mSv
- Annual dose in US = 6.2 mSv
- CT scan (foot) = 0.2 mSv
- 30 secs of fluoroscopy (foot) = 0.08 mSv
- 4 X-rays (foot) = 0.02 mSv

X-ray dosage

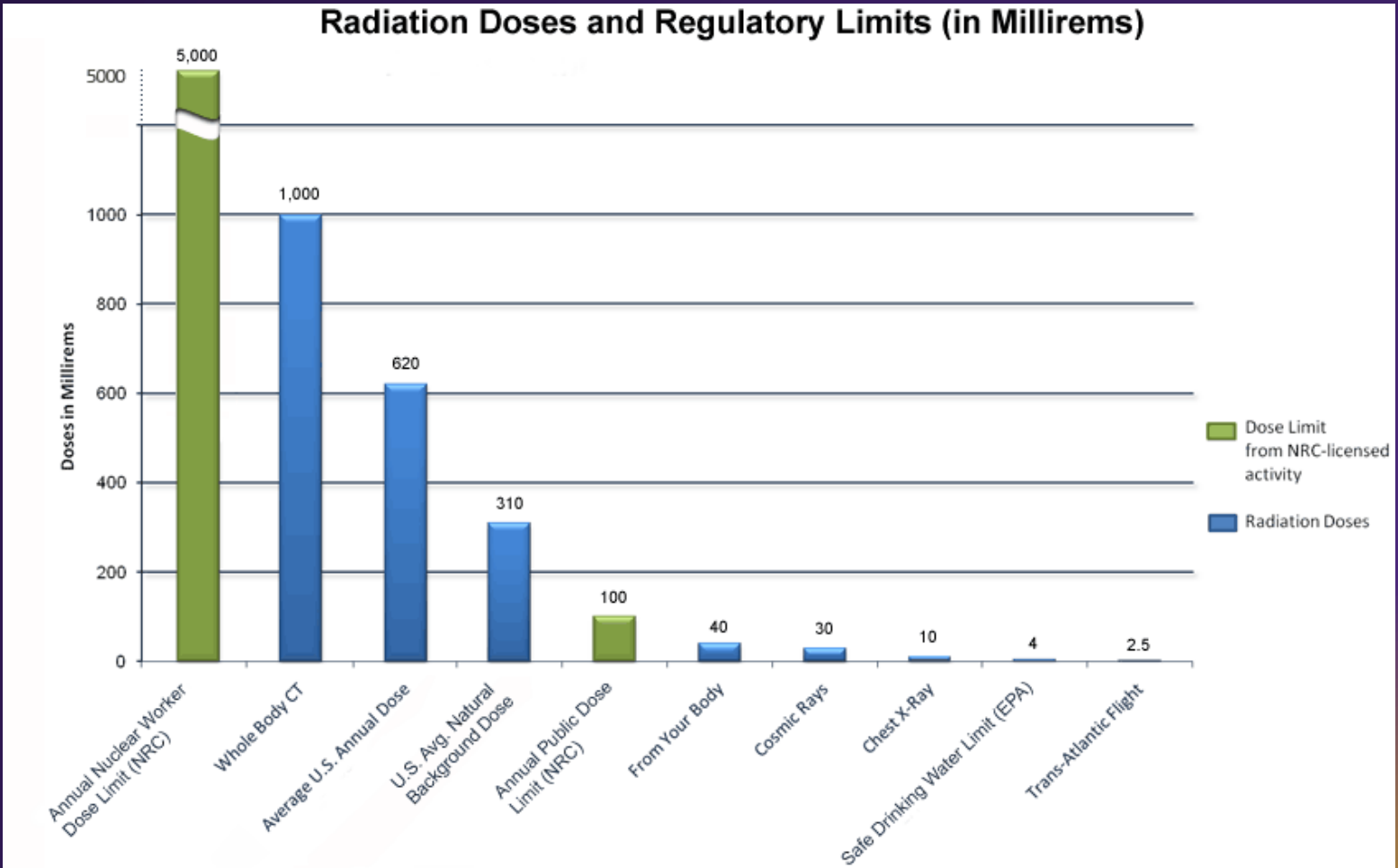

http://www.nrc.gov/about-nrc/radiation/around-us/doses-daily-lives.html

I. Computed tomography (CT)

- Images generated by detecting shadow in X-ray photons
- X-rays photons – same photons as visible light, just a higher energy, able to pass through soft tissue, absorbed by bone
- Patient lies on table, which moves through the CT scanner
- X-ray tube and detectors mounted on ring that rotates around table
- X-ray energy varied depending on tissue that is being scanner

Sir Godfrey Newbold Hounsfield



Hounsfield unit (HU) scale

- linear transformation of the attenuation
- radiodensity of distilled water is defined as 0 HU
- radiodensity of air at STP is defined as -1000 HU
- radiodensity of cortical bone defined as 1000 HU

Sir Godfrey
Newbold
Hounsfield

Multi-detector CT

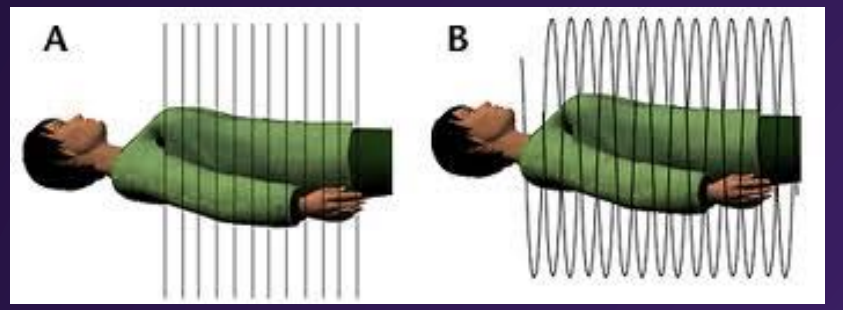

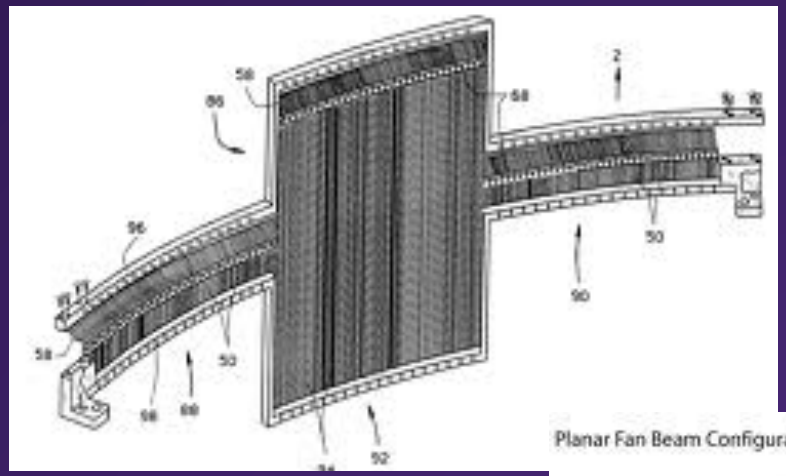

Key innovations:
Slip rings
Spiral scanning
Multi-detector arrays
Beam configurations

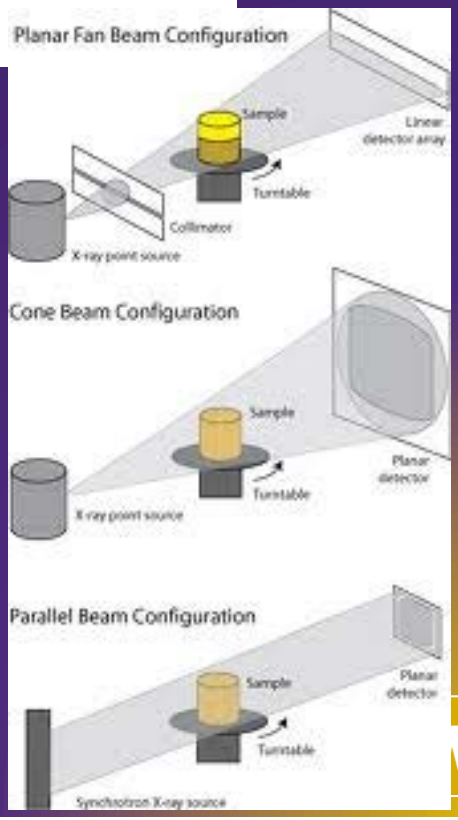

Axial multi-detector CT of foot

Three scans through ankle, subtalar joint, and metatarsals. Cortical and trabecular detail well seen; soft tissues only distinguishable when separated by fat.

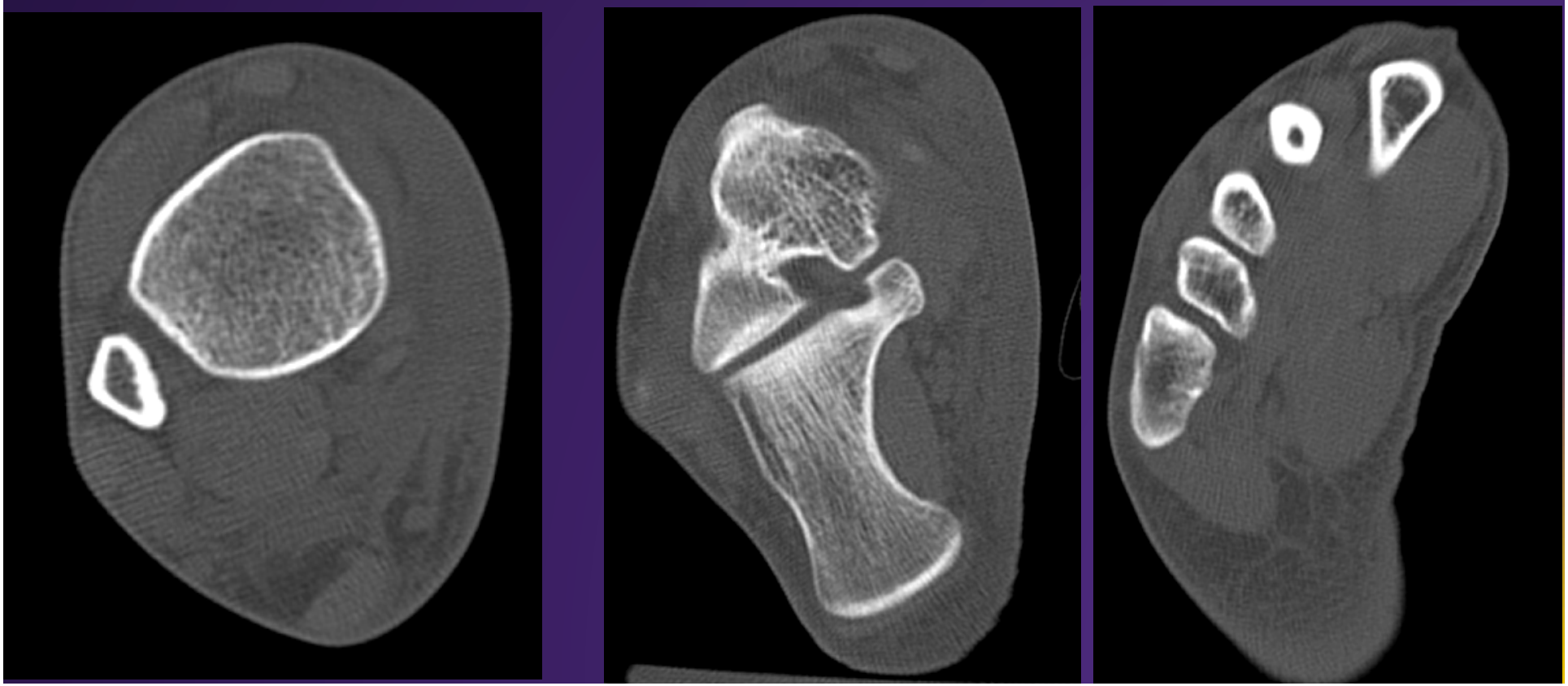

CT scans -- reformatted

We can take advantage of the near-isotropic resolution of multidetector CT scans (~0.5mm) to produce reformatted views in any plane. These are thin slices, but we could also produce simulated X-rays (digital reconstructed radiographs or DRRs). Note the tibial fracture.

What can we do with CT scans of the foot?

- Relatively easy to segment into separate bones
- Make submillimeter-accurate patient-specific 3D models of bones and their relative positions
- Collect data for active shape models
- Skin thickness, some muscle cross-sections
- Limited weight-bearing can be simulated
- No motion studies!

Metal artifact

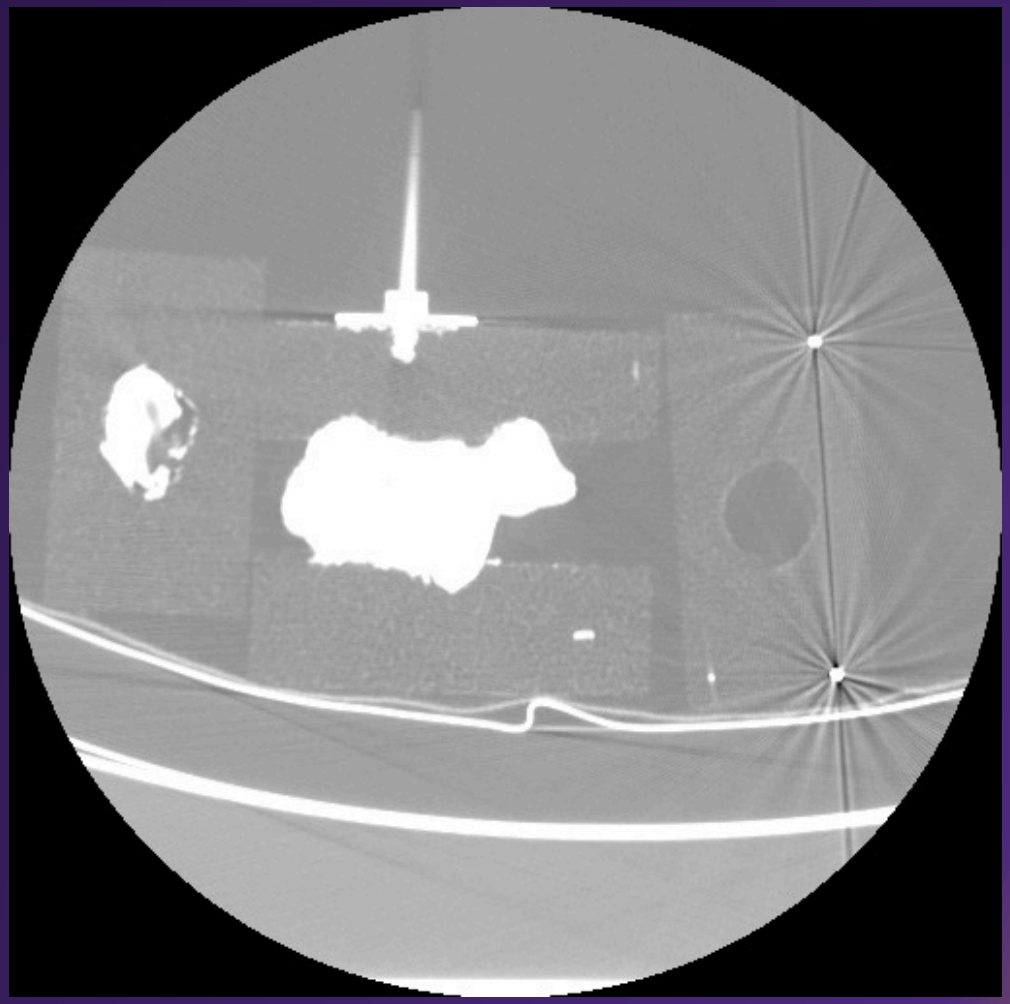

Metal artifact reduction

Gemstone Spectral Imaging (GSI): low (70 kV) and high (140 kV), interpolate in between

Metal Artifact Reduction Sequence (MARS): estimate intensity with no metal

Computer Tomography (CT)

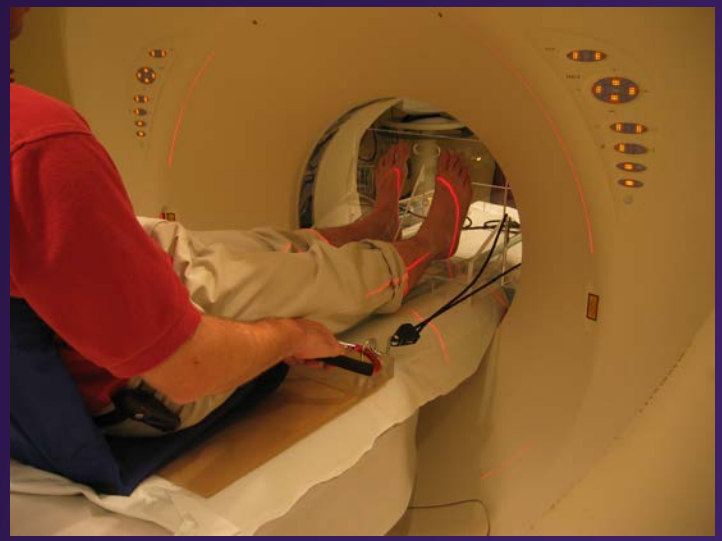

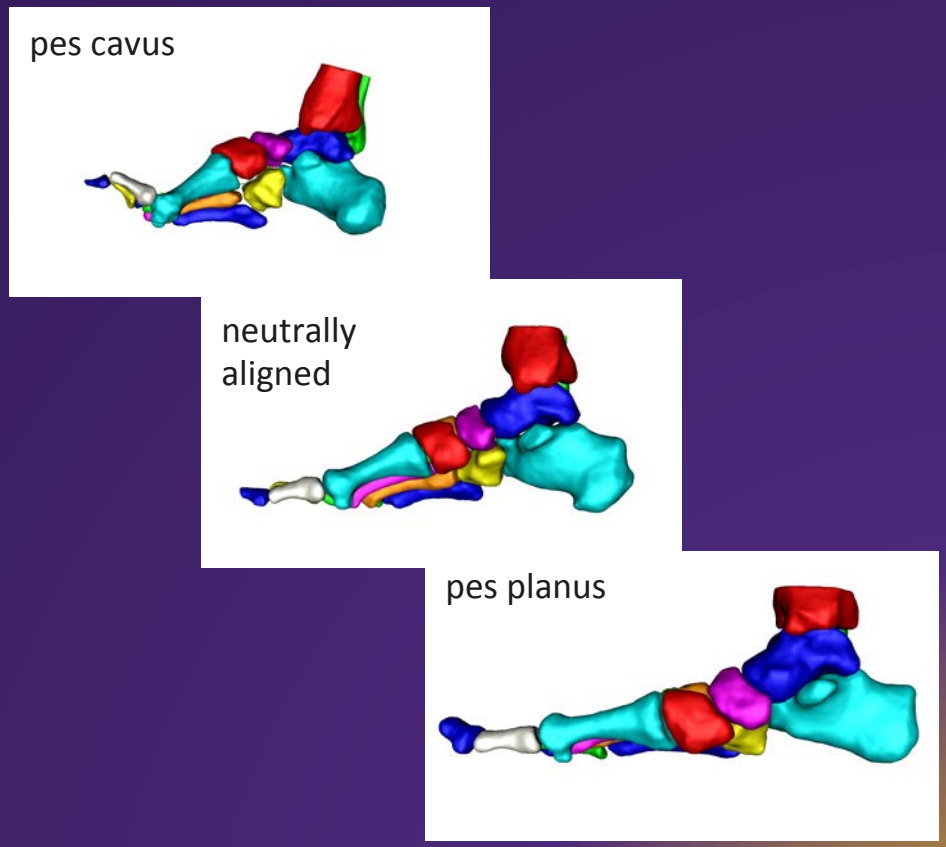

Ledoux WR, et al., J Orthop Research, 24, 2006

NIH Public Access
Author Manuscript
J Biomech Eng. Author manuscript; available in PMC 2010 July 2.

Published in final edited form as:
J Biomech Eng. 2009 September ; 131(9): 094502. doi:10.1115/1.3148474.

An Elaborate Data Set Characterizing the Mechanical Response of the Foot

Ahmet Erdemir[1,2], **Pavana A. Sirimamilla**[1,3], **Jason P. Halloran**[1], and **Antonie J. van den Bogert**[1]

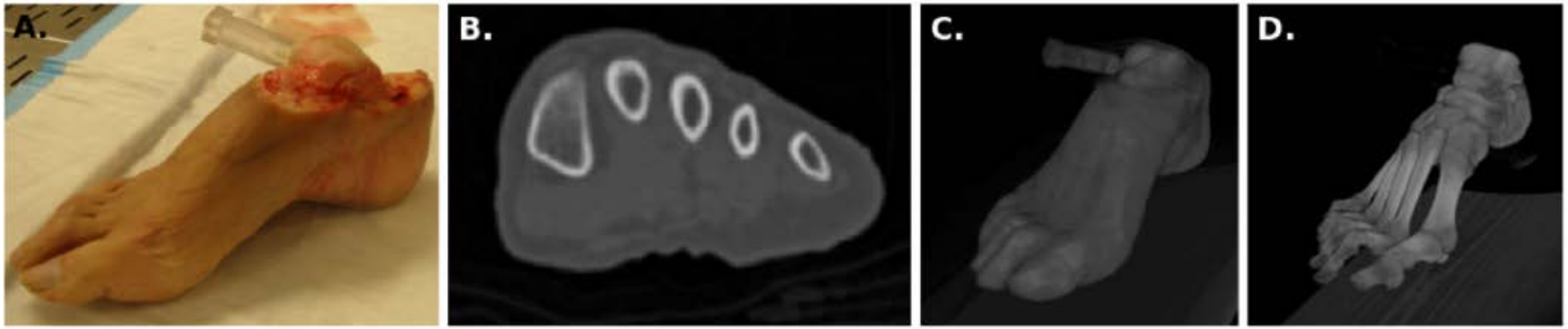

https://simtk.org/project/xml/downloads.xml?group_id=136

II. Ultrasound

- Images generated by generation of longitudinal pressure waves (1-50 MHz), and detection of reflections
- Half-λ thickness piezoelectric transducer functions as wave generator/sensor for reflected wave
- Reflection occurs at interfaces where acoustic impedance changes, with total reflection at interfaces with air/bone
- Axial resolution (0.3mm at 10MHz) typically better than lateral
- Real time (2D) or near-real-time (3D)
- Correlation-based speckle noise tracking for tissue motion, elastography

Generation of the ultrasound signal

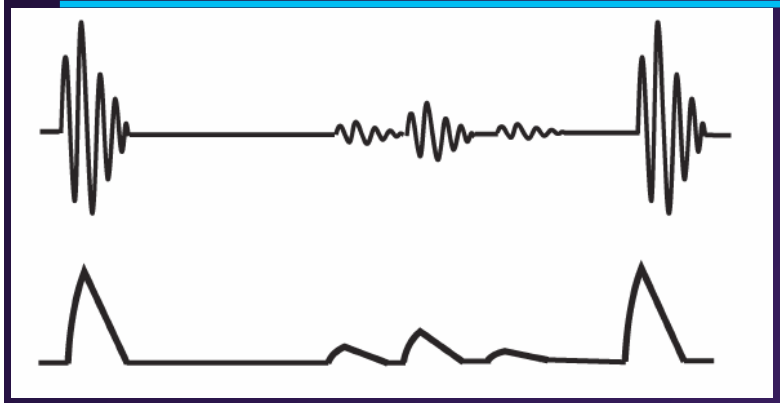

A

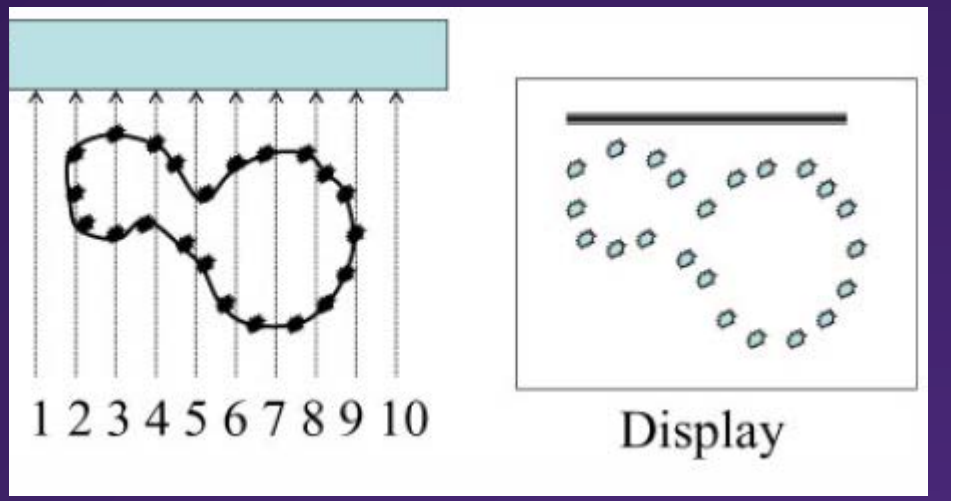

C

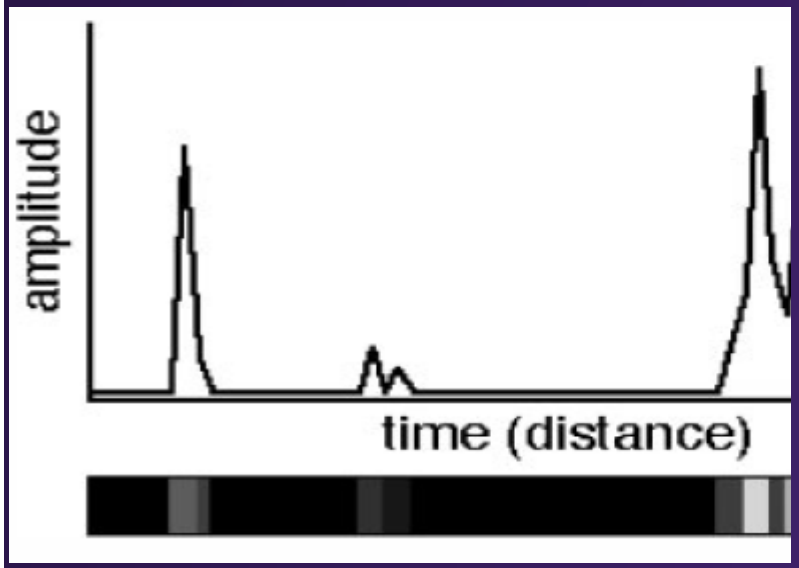

B

A: transmitted pulse and reflected echoes
B: conversion of echoes to one line in the image
C: buildup of whole image

Synovial imaging in RA

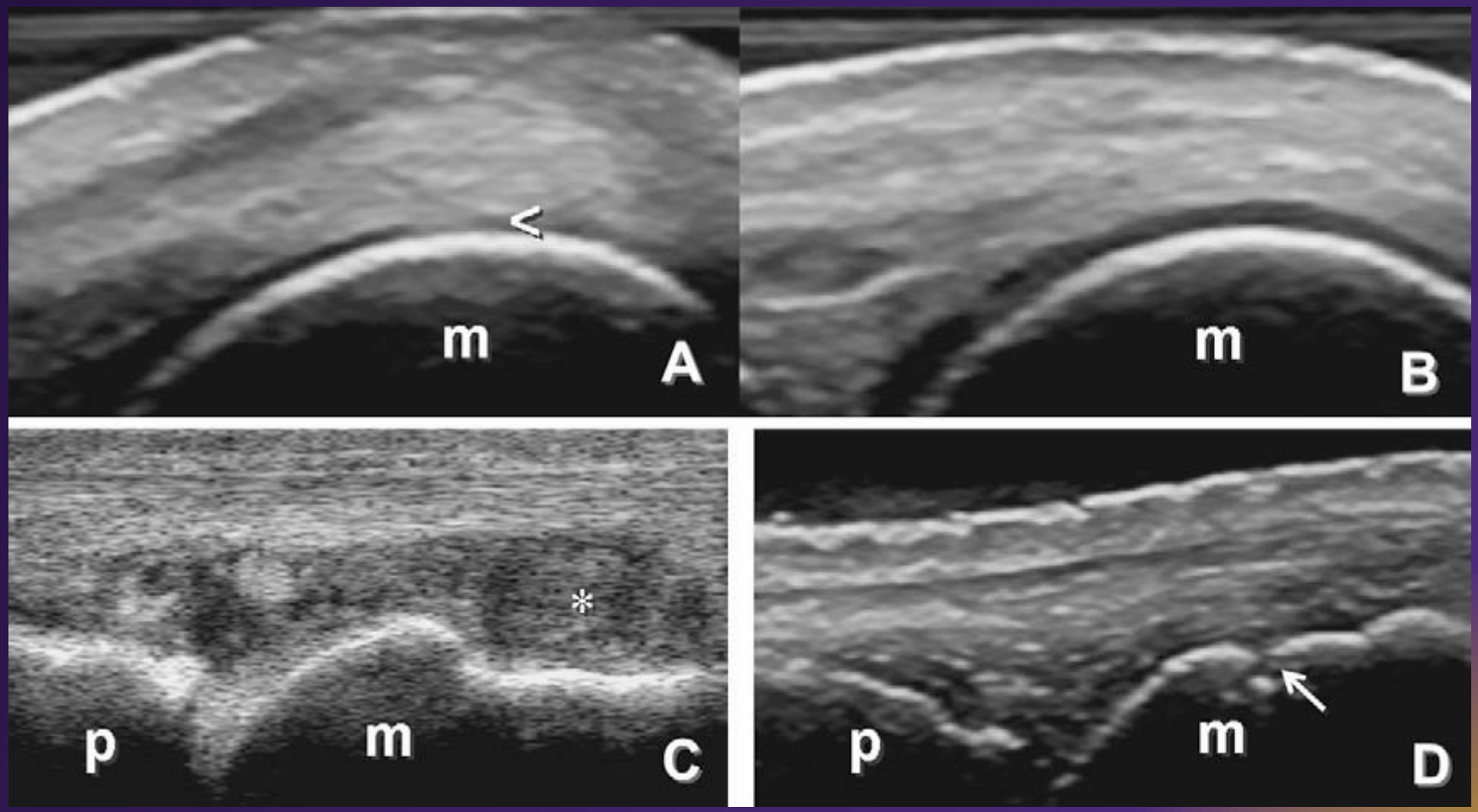

A: cartilage thinning over MC head
C: synovial proliferation

B: normal MC
D: bony erosion

Speckle generation

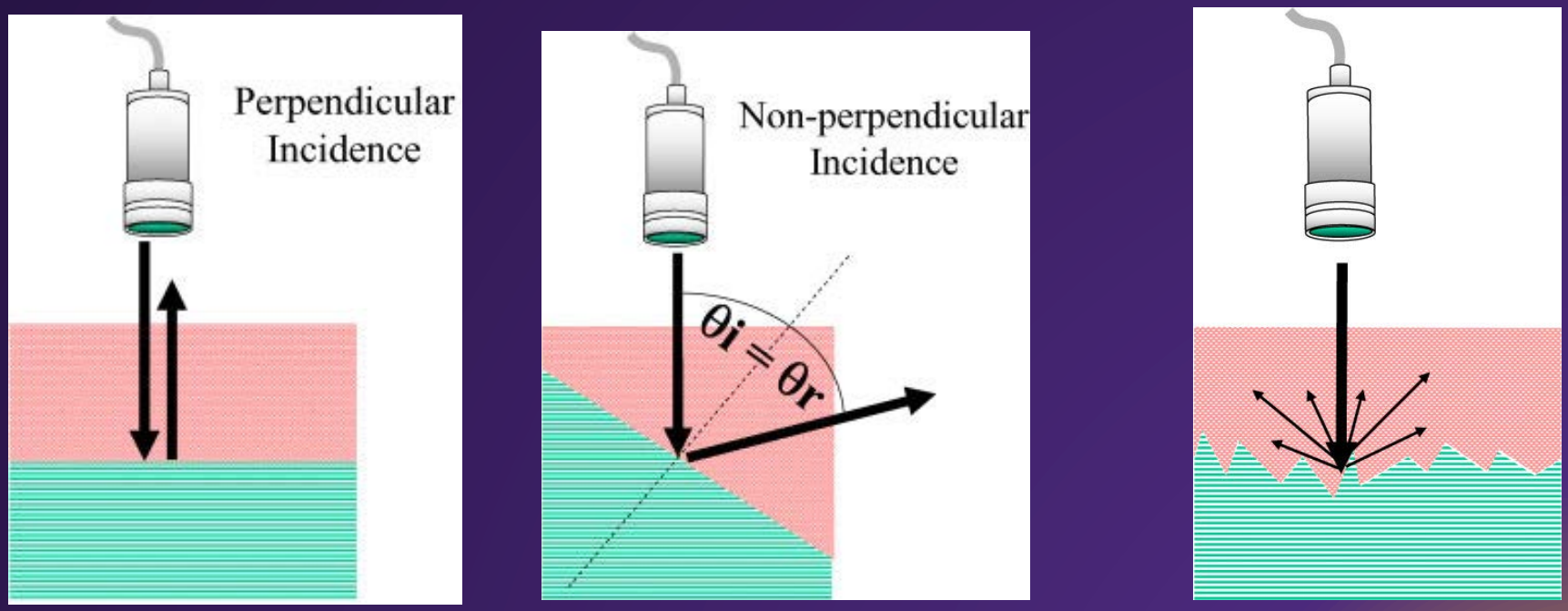

Left, specular reflection from a flat, perpendicular interface. Center, reflection from an oblique interface, with weaker return signal. Right, reflection from small scatterers (<0.1 λ) producing isotropic reflection.

Speckle tracking

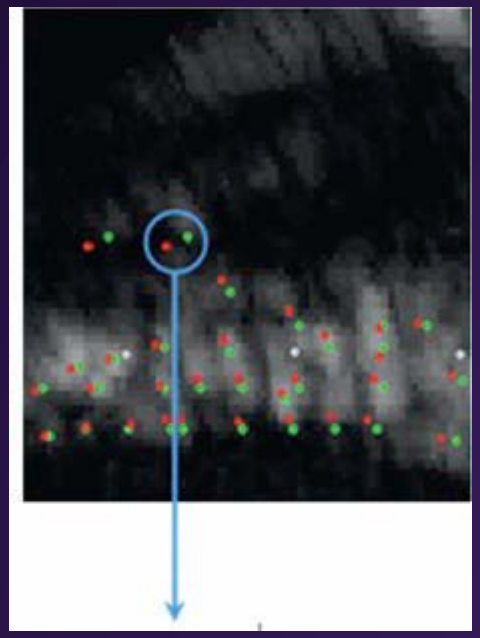

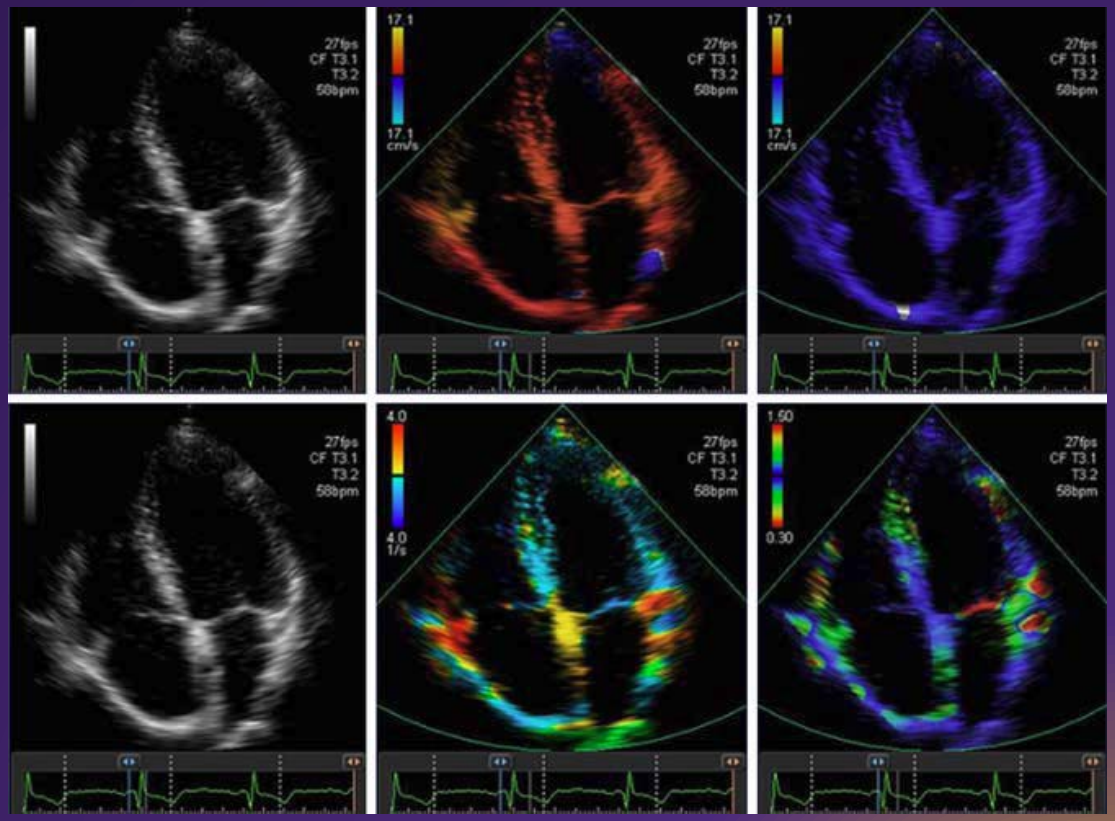

Correlation-based matching can be used either to find motion of corresponding points on images or in raw signal, yielding tissue motion and strain.

Ultrasound elastography

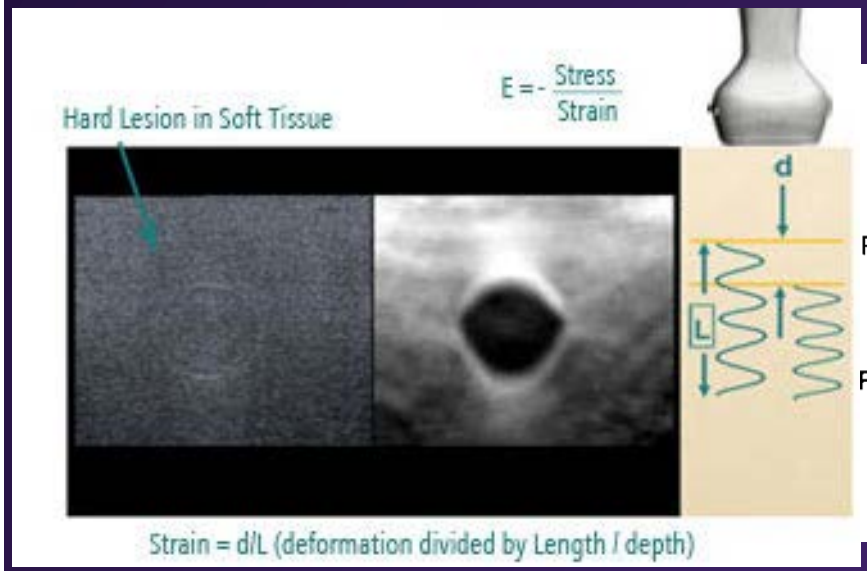

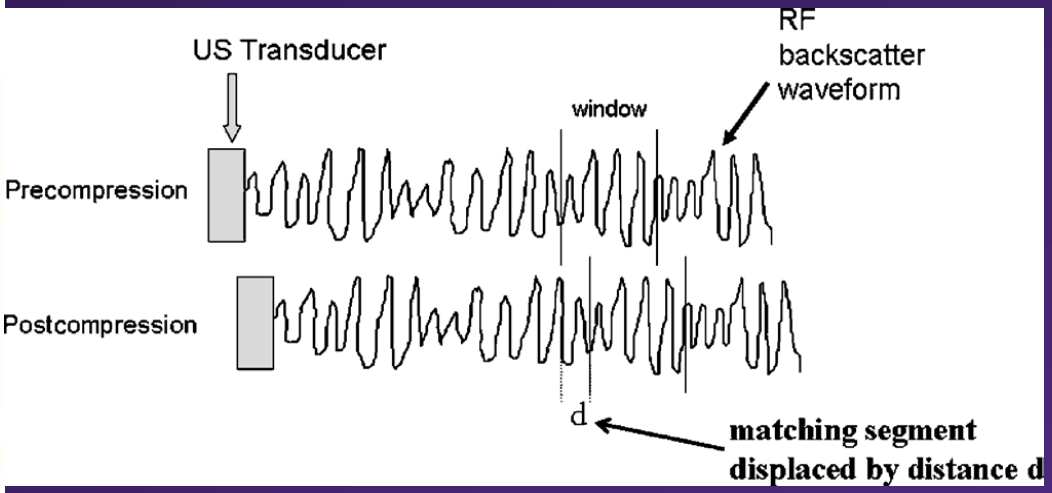

In ultrasound elastography, gentle compression is applied by the operator, and strain is measured throughout the image. Abnormal tissues (here, breast cancer) are frequently stiffer than normal tissues. Note that only the external stress is known.

Ultrasound elastography

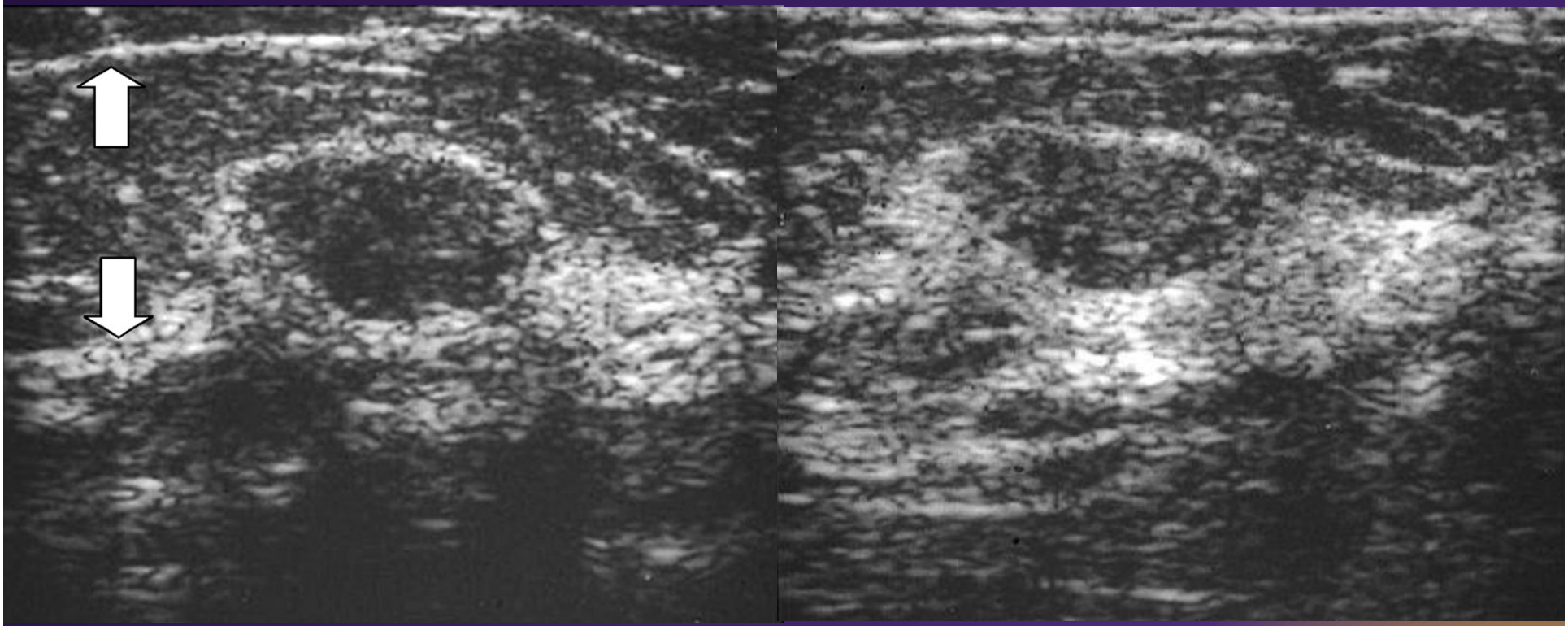

A stiff, nondeforming lesion inside normal breast tissue.

Ultrasound elastography

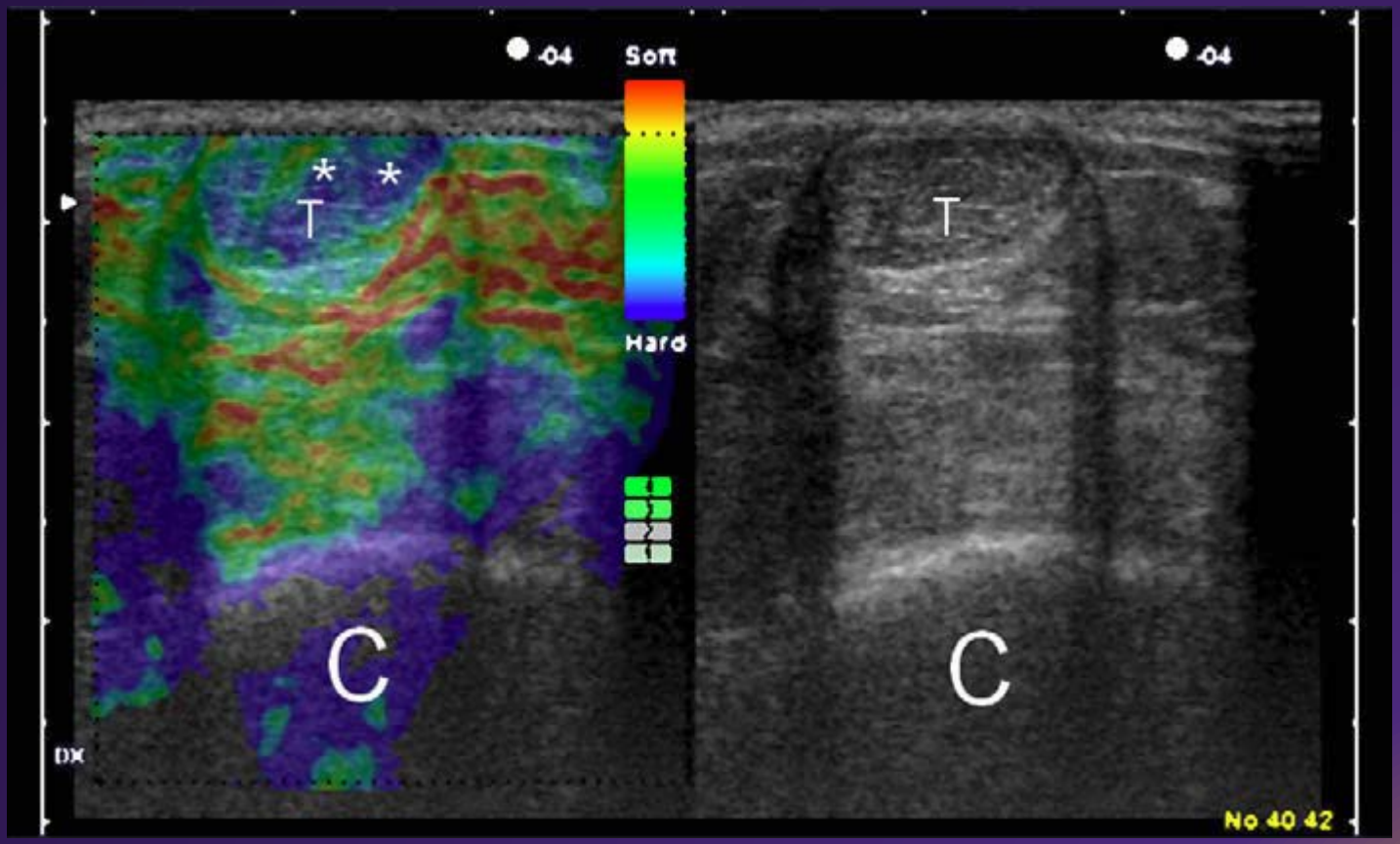

A second example. Here the lesion has both soft and hard components.

Ultrasound applications in foot biomechanics

- Plantar soft tissue stiffness
- Bone motion
- Tendon and muscle motion
- Moment arms (angular deviation vs. tendon motion)
- Surgical adhesions
- Distribution of strains in superficial tissues

Inverse FEM of heel pad stiffness

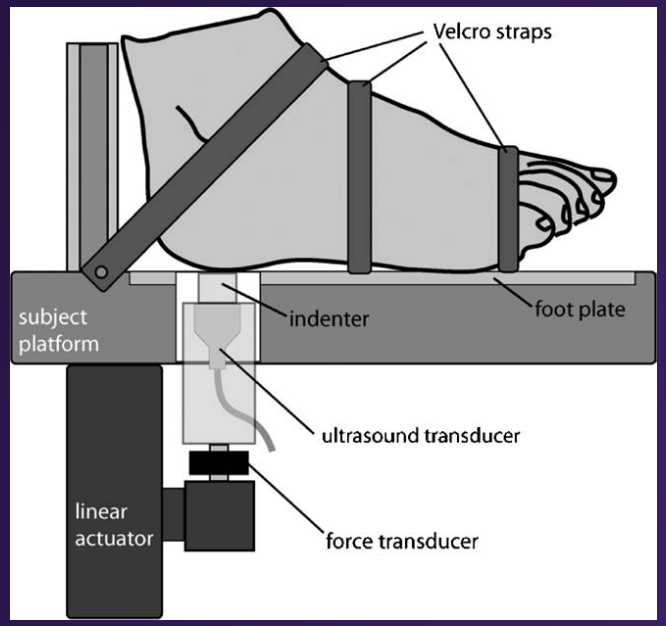

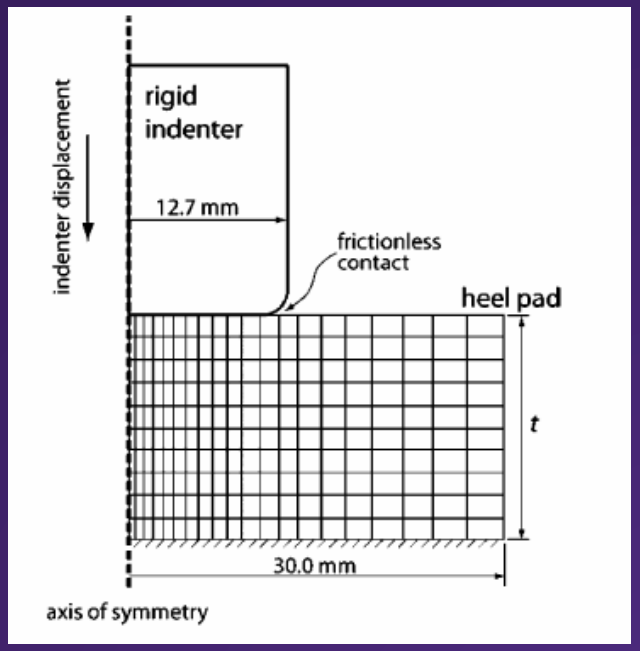

Axisymmetric model. Measured layer thickness only. Diabetics and normals not significantly different, but wide range of individual variation.

Erdemir et al., J Biomech 2006

Validation of MRI loading device

Validation of MRI loading device

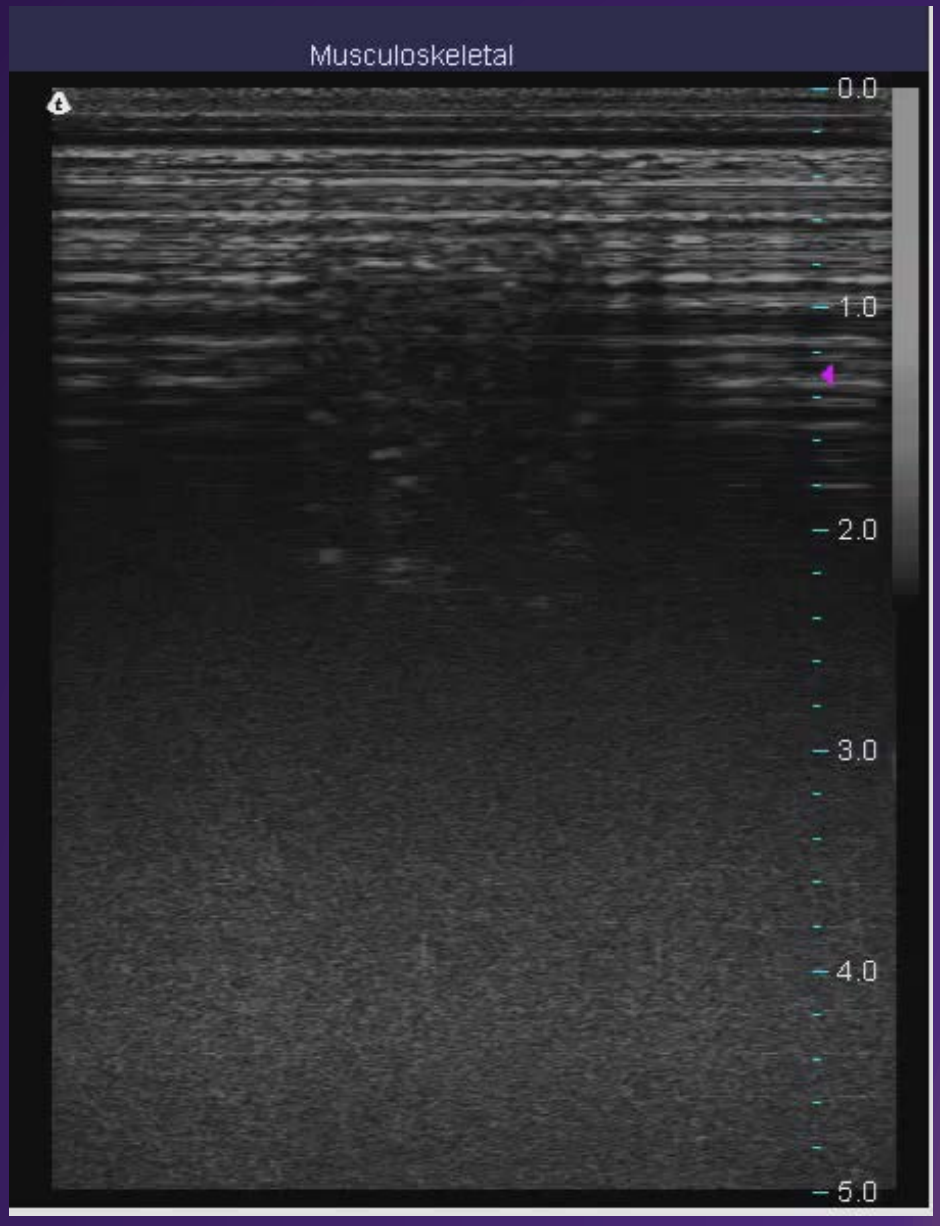

Tracking motions of the gastrocnemius and soleus with ankle motion

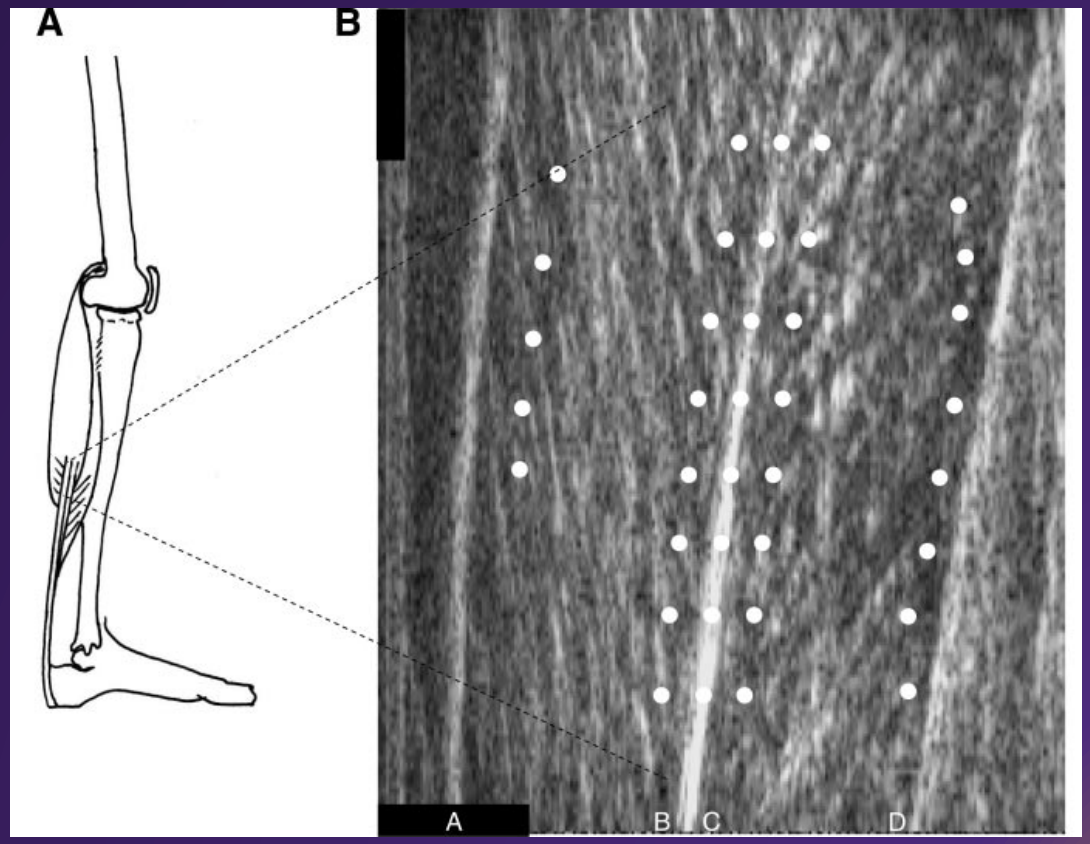

Muscle markers were used in this study rather than the musculotendinous junction.

Loram et al, J Appl Phys 2006

Results with active flexion/extension

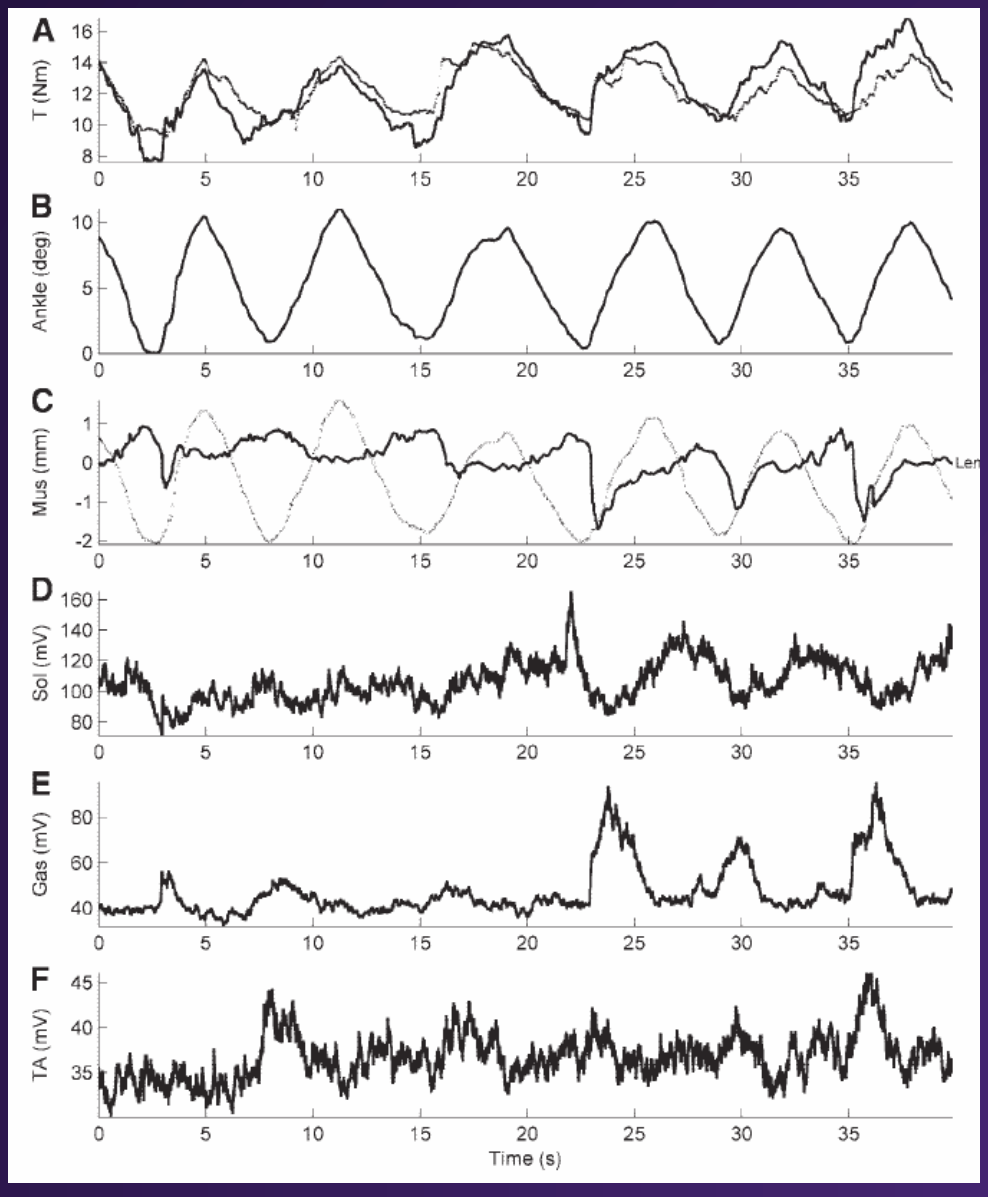

Note phase difference between gastrocnemius and soleus in C, and differential recruitment of the gastrocnemius over time. Method is capable of subpixel resolution (<20 microns) corresponding to very small motions (<0.1 degree of passive motion) because of signal averaging performed in the cross-correlation measurement.

Loram et al, J Appl Phys 2006

III. X-ray imaging (fluoroscopy)

- Images generated by detecting shadow in X-ray photons
- X-rays photons – same photons as visible light, just a higher energy, able to pass through soft tissue, absorbed by bone
- Area of interest of patient is placed between X-ray tank (source) and image intensifier (II); often this is done was the patient is on a table, but that is not required
- X-ray energy varied depending on tissue that is being scanned
- Fluoroscopy rooms used for bypass surgery
- Portable machines (i.e., C-arms) often used for orthopaedics

X-ray measures of foot type

- Faxitron X-ray cabinet and digital scanner
- All specimens loaded to 25% body weight and standard clinical X-rays taken

Hindfoot Alignment

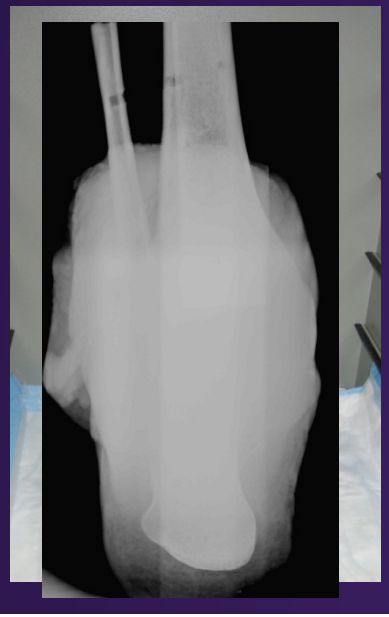

Anterior-Posterior (AP)

X-ray measure of foot type

- Lateral view
  - Lateral talometatarsal angle (LTMA) (Sangeorzan et al, Foot & Ankle, 1993)
  - Calcaneal pitch angle (CPA) (Sangeoran et al, Foot & Ankle, 1993)
  - Navicular height (Ellis et al., JBJS, 2000)

X-ray measure of foot type

- AP view
  - Talonavicular coverage angle (TNCA) (Sangeorzan et al, Foot & Ankle, 1993)
- Hindfoot alignment view
  - Calcaneal eversion distance (CED) (Saltzman and el-Khoury, FAI, 1995)

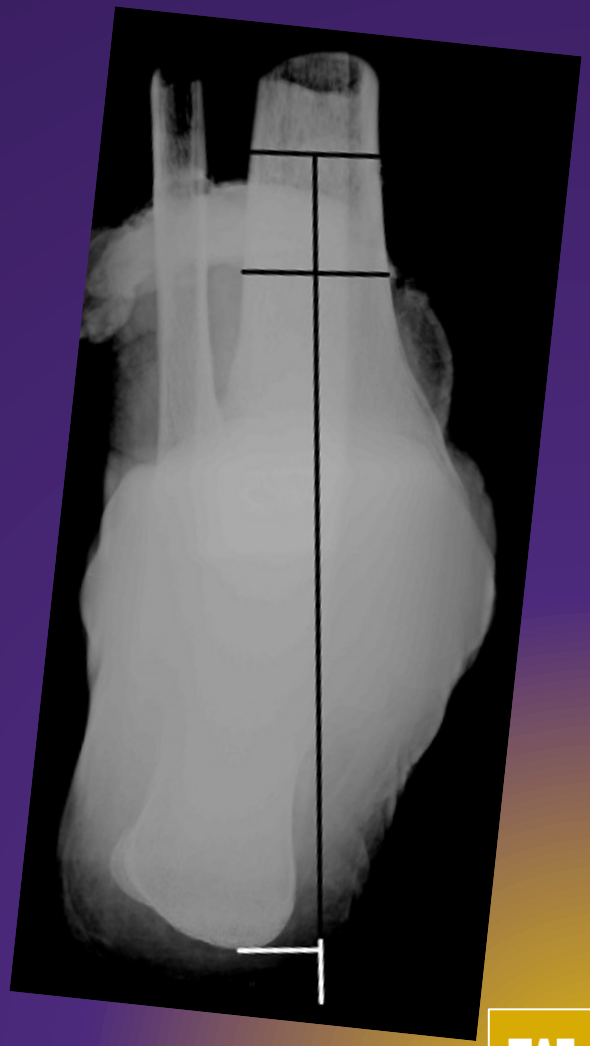

Clinical foot and ankle X-rays with cadaveric specimens , Roush et al., in review FAI

X-ray imaging

Wilhelm Roentgen

Modern C-arm, image intensifier at top

The insides of an II

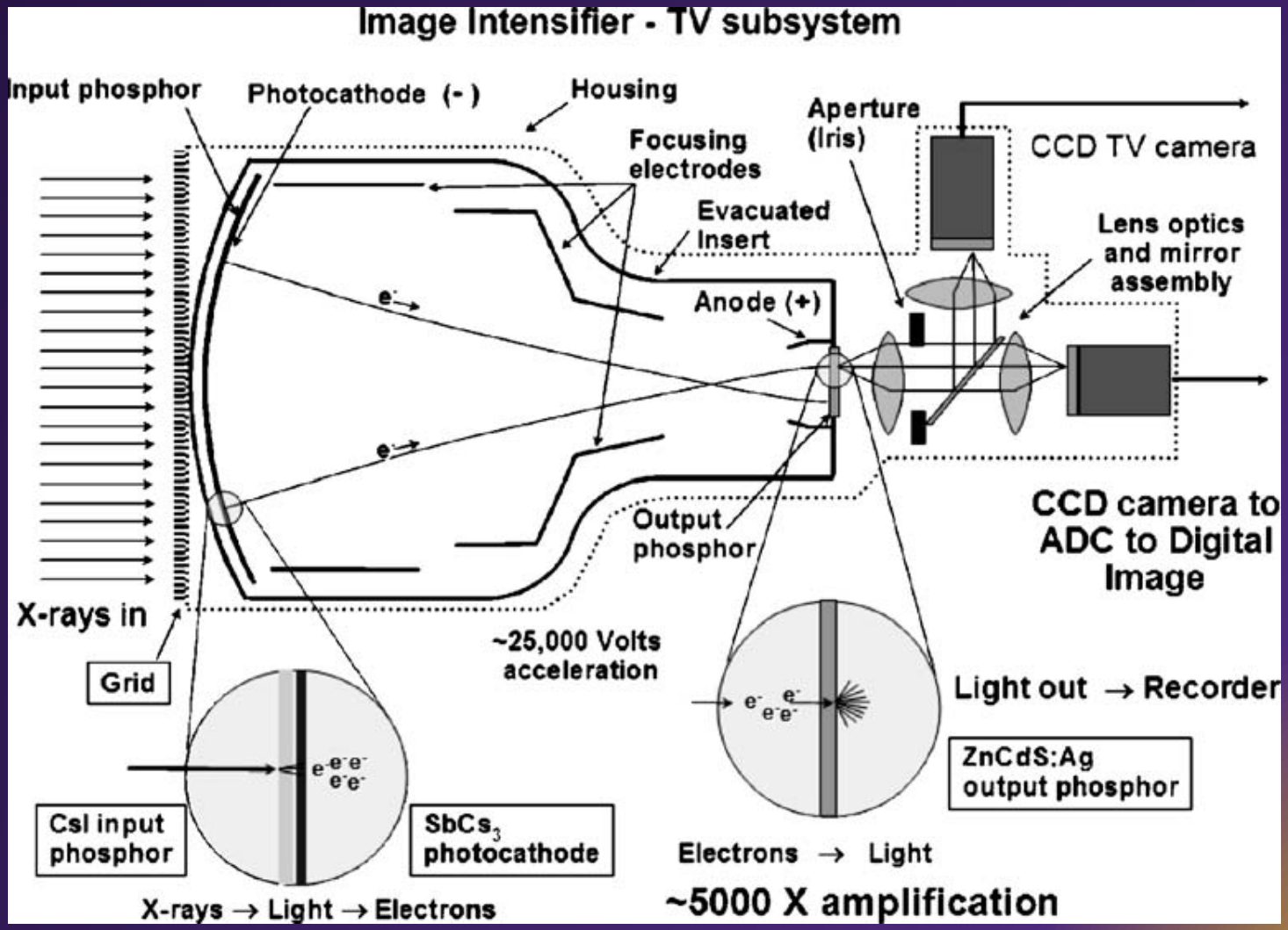

Distortion arises from the influence of external magnetic fields on the paths that electrons follow inside the II.

Image intensifiers produce position-dependent image distortion





Predistortion images (summed over multiple positions) demonstrates distortion and variability with position. After a separate correction is applied at each position, appearance of the grid no longer demonstrates distortion or variability.

Two independent calibration steps

- Correct 2D distortion (repeat if system moved)
- Using a phantom, determine the focal length (distance between X-ray source and image plane), pixel dimensions (more stable) and intrinsic parameters of the camera
- Validate by comparing computed images of 3D phantom to actual images

Flat-panel detectors

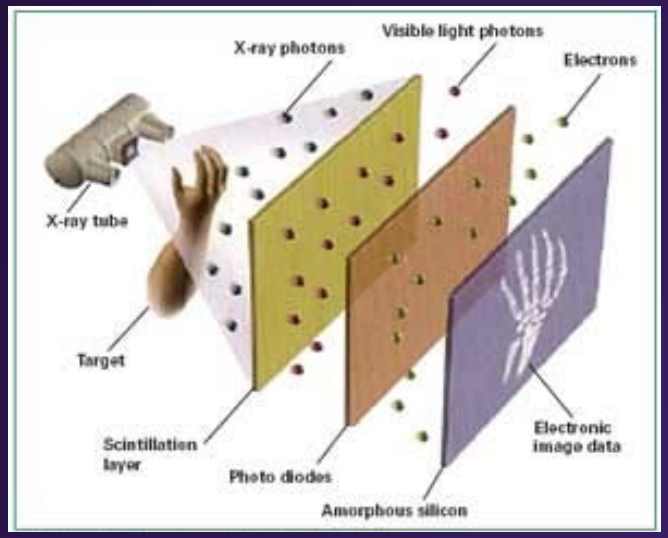

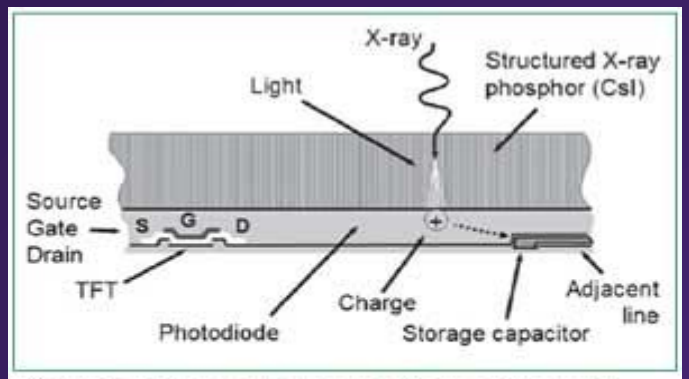

Figure 5: *Cross-section of an indirect TFT detector using a CsI scintillator shows the conversion of x-rays first into light, traveling through the structured phosphor to a photodiode etched on the TFT arrays, and the creation of a proportional charge stored in the local capacitor.*

- Array of elements that generate signals directly
- Three layers – scintillator, photodiode, transistor array
- No distortion, wide dynamic range, linear response, better efficiency
- Current generation has long lag time, limiting frame rate to 30/s

Three biplane systems



VA Puget Sound

U. Pittsburgh

Brown

Biplane imaging – now what?

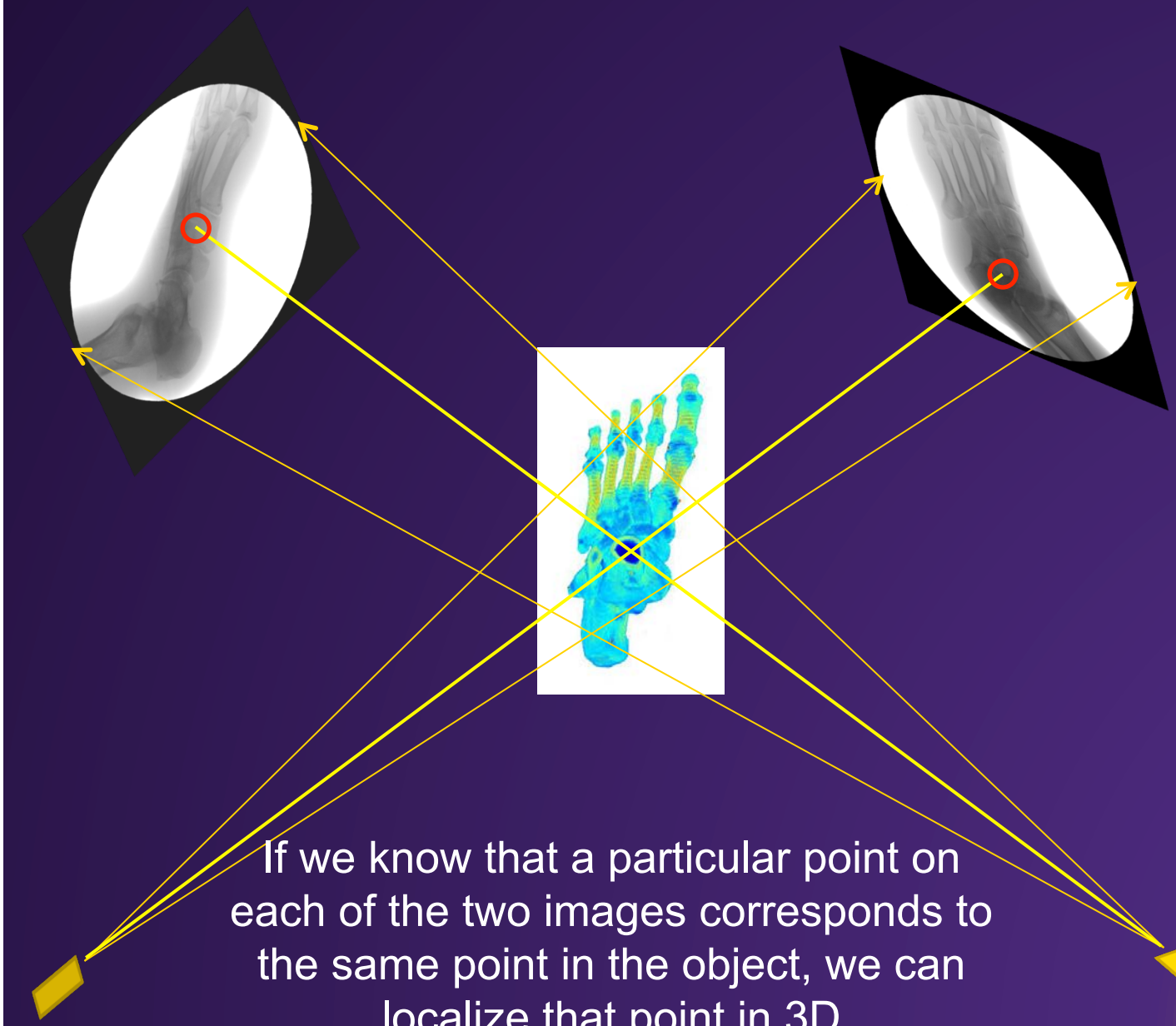

Schematic of single frame pair from a calibrated and distortion-corrected biplane system. (note that one projection is suboptimal). How to localize each of the separate bones in space?

If we know that a particular point on each of the two images corresponds to the same point in the object, we can localize that point in 3D.

IV. Magnetic Resonance Imaging (MRI)

- Takes advantage of body's natural magnetic properties
- Hydrogen protons = little bar magnetics, randomly aligned
- In a strong magnetic field (1.5 T or 3T), they line up
- Add a source of energy (radio waves, RF), hydrogen resonates
- Strength magnetic field altered with gradient coils
- Altering the local magnetic field by these small increments, different slices of the body will resonate as different frequencies are applied

Magnetic Resonance Imaging (MRI)

- RF source turned off, magnetic alignment returns, RF signal emitted – this signal is used to create the images
- Receiver coils around body sense the RF signal, intensity if plotted in grey scale
- Multiple RF pulses can be used in sequence for different tissues, which relax at different rates
- T_1 = longitudinal relaxation
- T_2 = transverse relaxation
- Proton density = Measures the signal strength from different tissues based only on the relative densities of hydrogen atoms

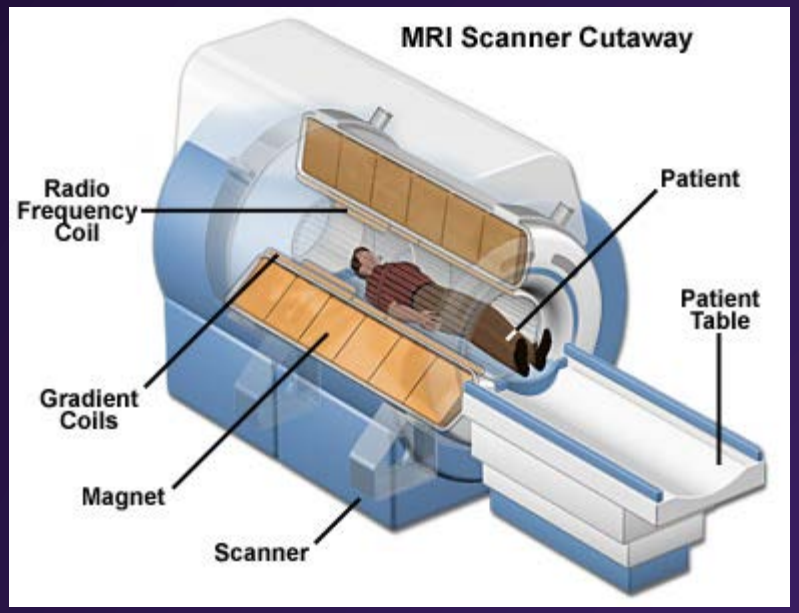



Peter Mansfield and Paul Lauterbur

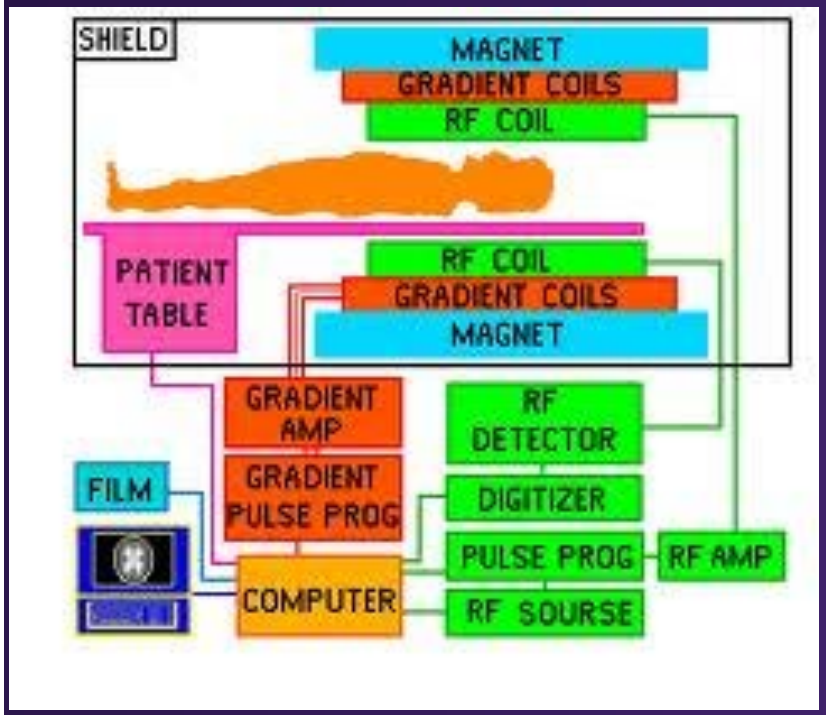

MR pulse sequence

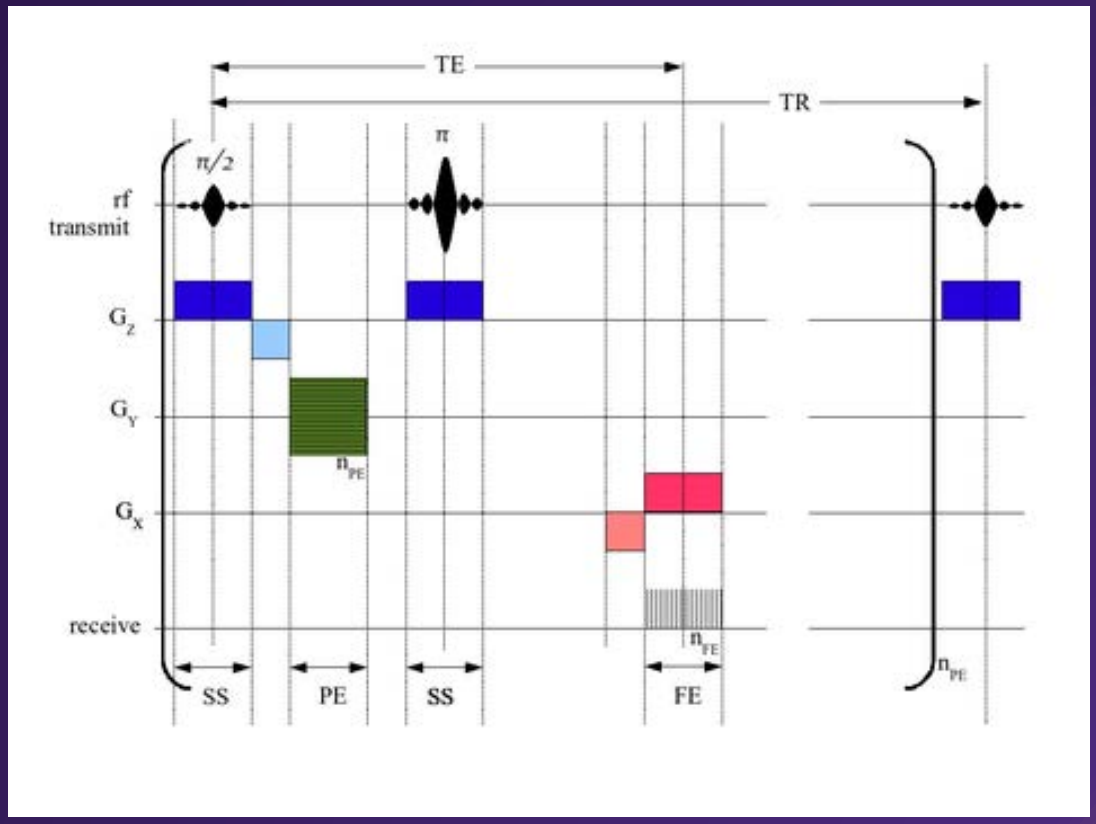

An MR pulse sequence is a program for each of the approximately half-dozen independent functional units in the scanner. Gradients are used for spatial localization and motion/diffusion sensitization. By manipulating TR, TE, sensitivity to T_1 and T_2 is changed.

MR pulse sequence

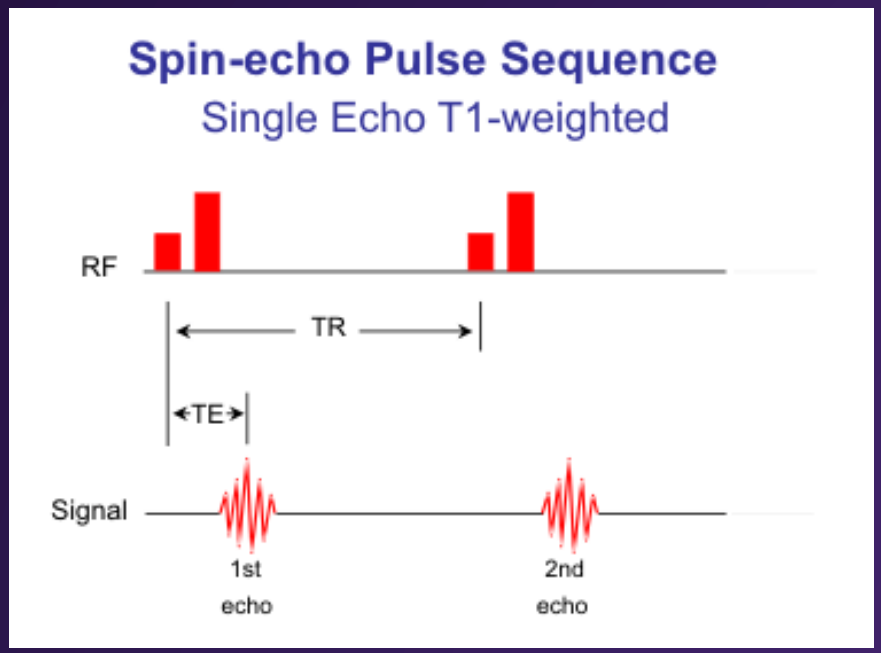

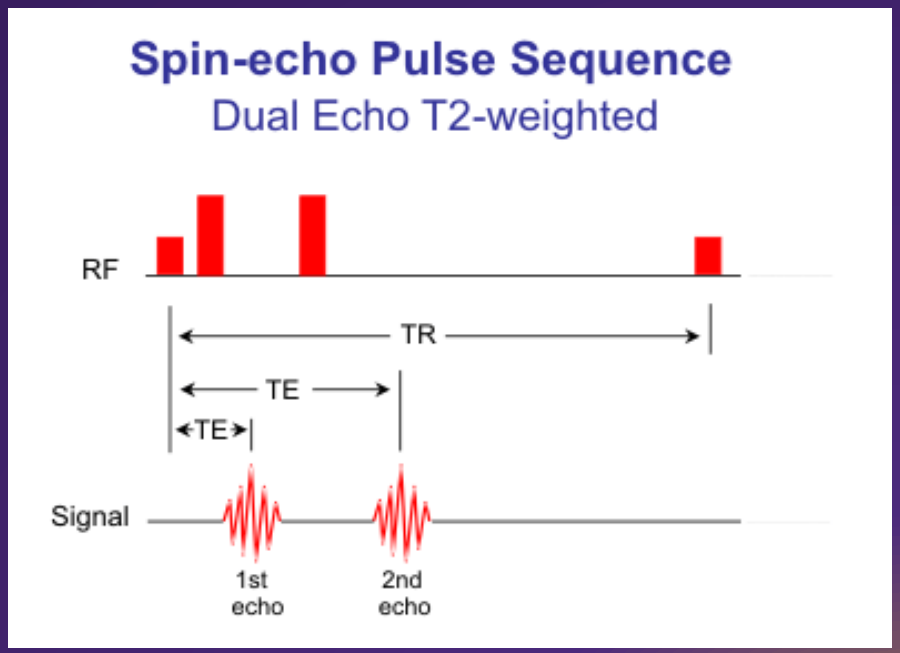

T_1-weighted and T_2-weighted

MRI and tissue properties

- T_1, T_2, proton density – tissue contrast
- Elastography
- Diffusion tensor imaging – coherent microstructure
- T_2 exercise effect

- 2D/3D – make motion studies possible
- Loading devices can (imperfectly) simulate weight-bearing
- SNR $\propto$(field)(voxel volume)(imaging time)$^{0.5}$

Different tissue contrasts result from different sequences

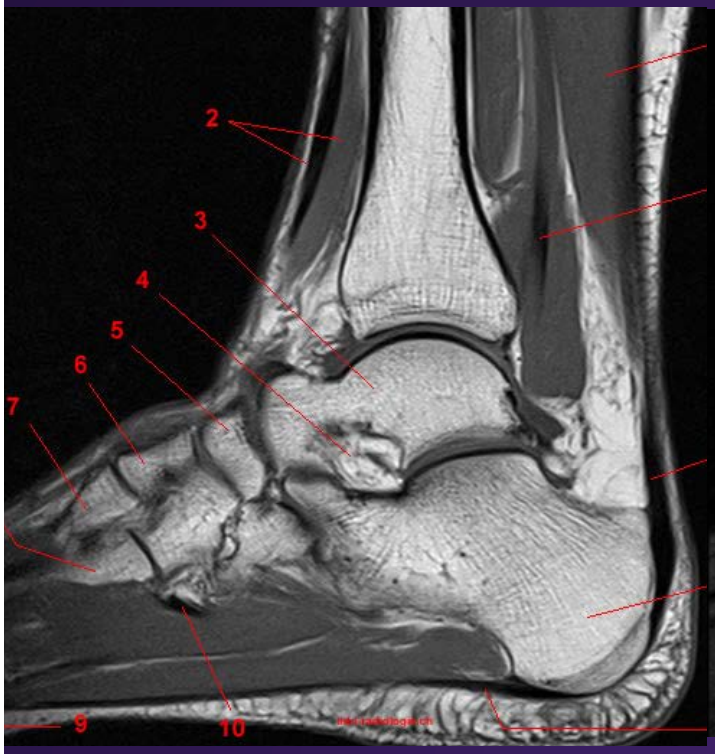

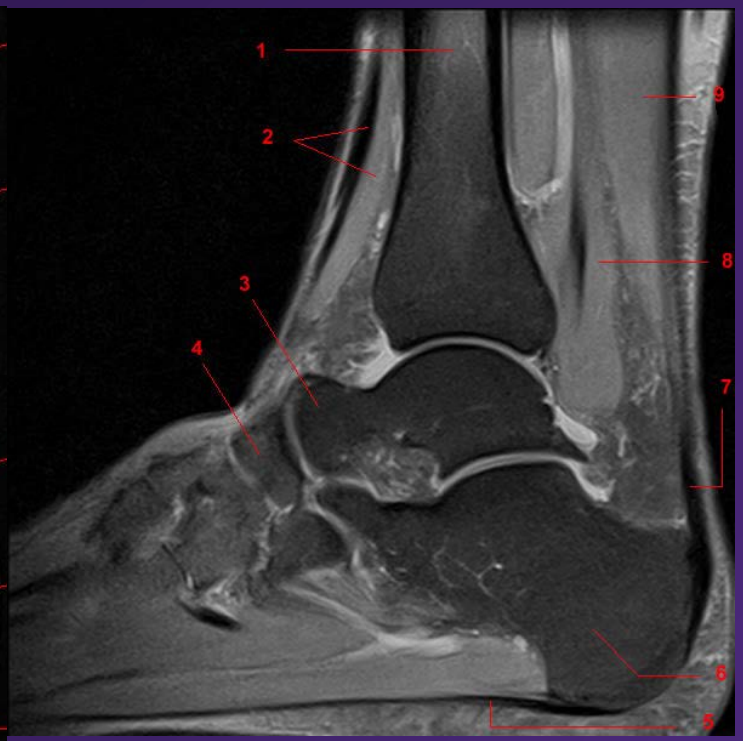

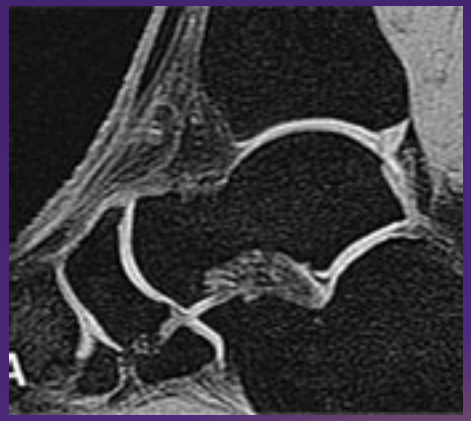

1) Sagittal T_1-weighted, 2) fat-suppressed T_2-weighted, and 3) fat-suppressed SPGR images (for cartilage) of the ankle.

MR Elastography

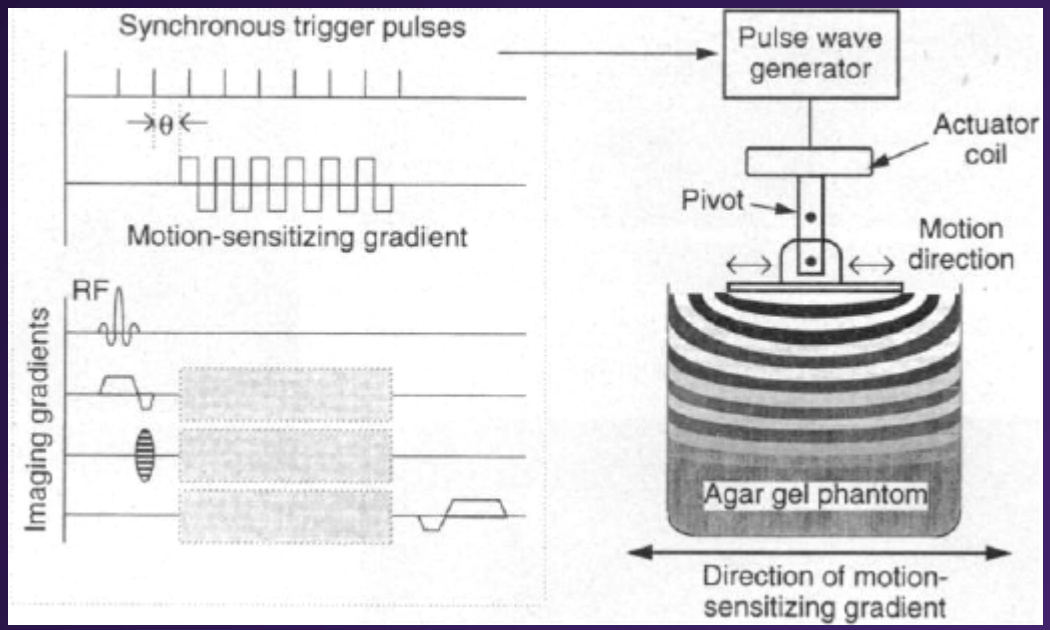

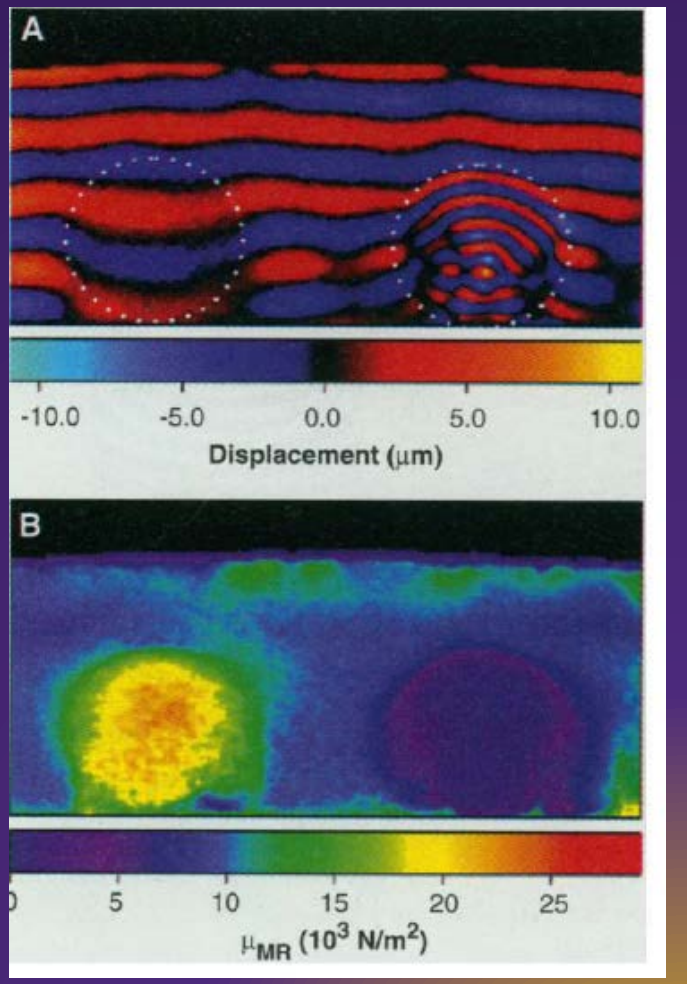

Longitudinal shear waves are produced; their wavelength in the transverse direction increases with tissue stiffness. The actual motion amplitude is measured in microns.

Muthupillai et al., Science 1995

MRE to measure liver stiffness

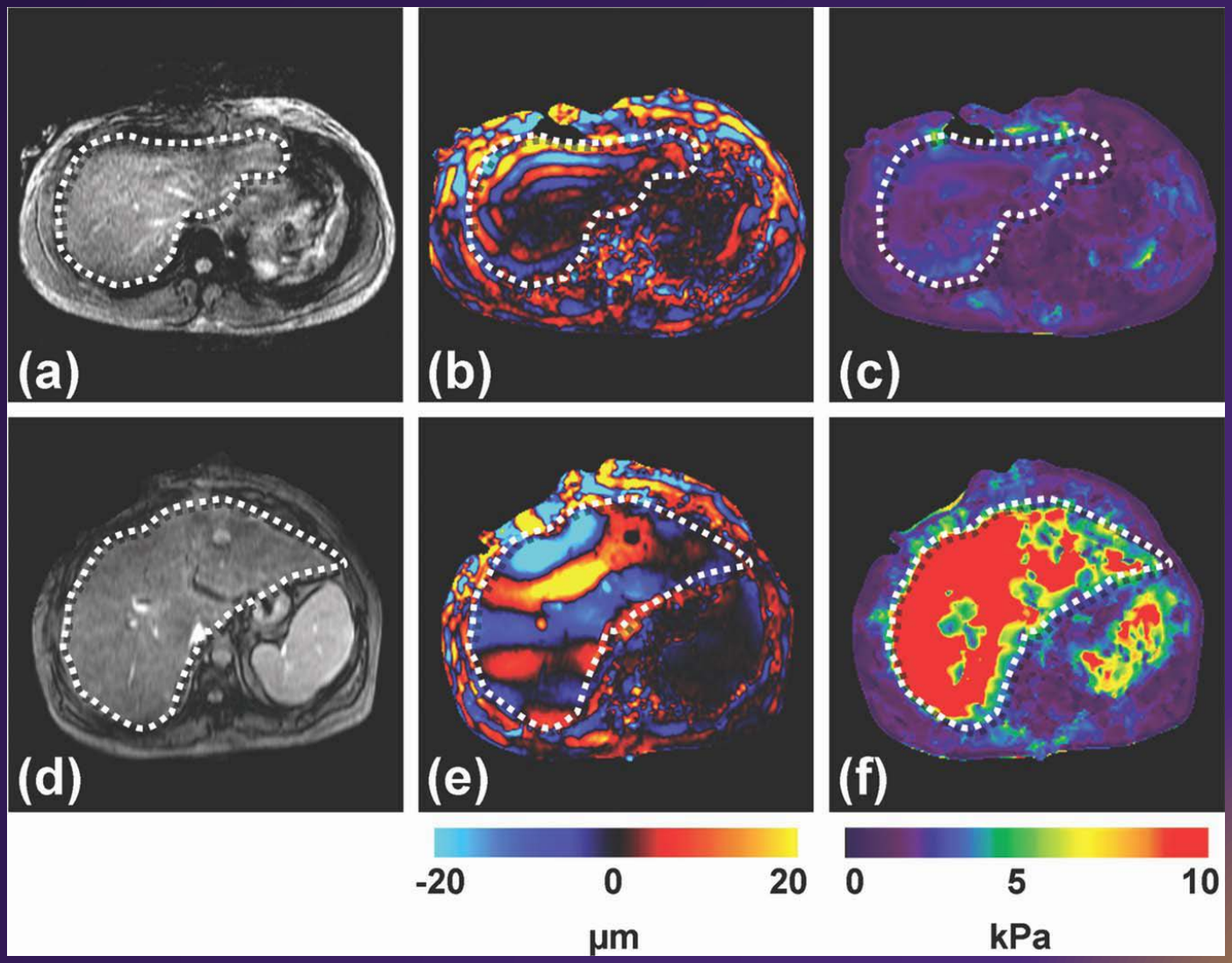

Normal liver, top; cirrhotic liver, bottom. Scarring increases stiffness.