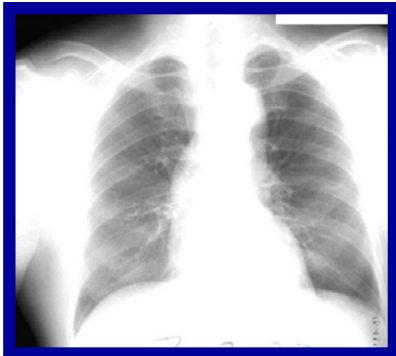

THERAPY OF ANAEROBIC INFECTIONS

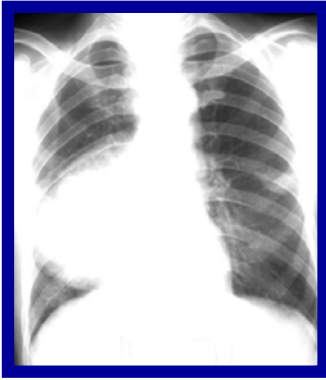Douglas Black, Pharm.D.
Associate Professor
School of Pharmacy
University of Washington
dblack@u.washington.edu

WE START OFF WITH 5
EXAMPLES OF ANAEROBIC
INFECTIONS...

NORMAL CHEST X-RAY



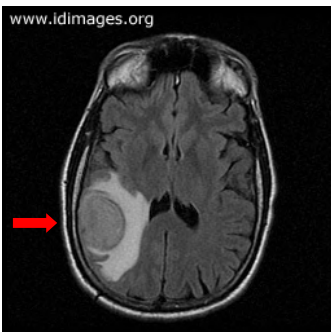
LUNG ABSCESS



LUNG ABSCESS

- A lung abscess is a localized pus cavity in the lung
- May be a complication of pneumonia or of large-volume aspiration
- Often associated with periodontal disease
- Single abscesses are most common
- Anaerobes are prevalent, but aerobes are often involved as well
- Treatment: antibiotics (often with surgical drainage). Clindamycin is a good choice (not metronidazole). Penicillin G might be effective.

BRAIN ABSCESS (CT SCAN)



BRAIN ABSCESS: DETAILS

- Organisms gain access to the brain hematogenously, directly from a contiguous infected site, or after trauma or surgery. The mouth is a common source.
- Most common symptom: headache
- Usual organisms: streptococci plus anaerobes
- Dx made by CT or MRI
- Treatment: surgical drainage plus prolonged antibiotics. DOC: metronidazole + ceftriaxone.

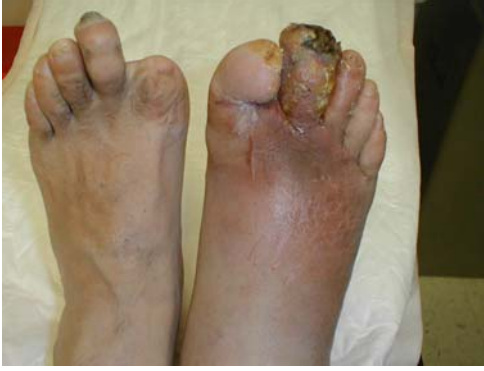INTRA-ABDOMINAL INFECTION

- Primary (spontaneous bacterial peritonitis) or secondary
- Organisms
 - SBP: monomicrobial (enteric GNR)
 - Secondary: polymicrobial (enteric GNR + anaerobes)
- Hospital-acquired infection has a high mortality rate
- Treatment
 - SBP: antibiotics plus longterm prophylaxis
 - Secondary: surgical repair plus antibiotics

PELVIC INFLAMMATORY DISEASE (PID)

- Infection of the female reproductive organs
- Can involve the Fallopian tubes, cervix, uterus, and ovaries
- Peak incidence: late teens, early 20s
- Presentation is nonspecific
- Organisms: NG, *Chlamydia*, enteric GNR, anaerobes
- Complications: sterility, ectopic pregnancy
- Treatment: aggressive antimicrobial therapy (oral OK if infection is mild)

DIABETIC FOOT INFECTION



DIABETIC FOOT INFECTION: DETAILS

- A serious complication of diabetes that may lead to amputation (not all diabetic foot ulcers are infected)
- Poor circulation results in thin and vulnerable skin; diabetes-associated neuropathy may impair sensation and therefore awareness of foot trauma
- Symptoms include redness, swelling, and pain
- Bacteriology: mixed aerobic/anaerobic organisms, difficult to identify
- Treatment: surgical debridement plus broad-spectrum antibiotics (not necessarily with curative intent)

IMPORTANT ANAEROBIC ORGANISMS IN MEDICINE

- Above the diaphragm: *Peptostreptococcus*, *Bacteroides* spp., *Fusobacterium*, *Prevotella*, *Porphyromonas*
- Below the diaphragm: *Bacteroides fragilis* group (multiple species including *B. fragilis*), other *Bacteroides* spp.
- Other important anaerobes: *Clostridium* spp., *Propionibacterium acnes*, *Actinomyces*

TREATMENT PRINCIPLES

- Anaerobic infections are usually polymicrobial; what needs to be targeted?
- Anaerobic infections have a typical putrid smell which is helpful in identifying them
- Adequate surgical debridement and/or drainage is probably more important than the antibiotic therapy
- Abscess formation is a routine feature of anaerobic infections, and drug penetration into the abscess must be considered

THE EVIL ABSCESS

- Why is the abscess environment hostile to so many antibiotics?
 - Low pH, low redox potential
 - Inoculum effect
 - Dead bacteria and debris may inactivate drugs
 - β lactamase is often plentiful
- What antibiotics penetrate abscesses well?
 - Clindamycin
 - Metronidazole
 - Chloramphenicol (generally avoided)
 - **NOT β -LACTAMS!!!**
- Since drug penetration into abscesses is so poor, we use aggressive dosing (adjusted for renal or hepatic dysfunction) for anaerobic infections

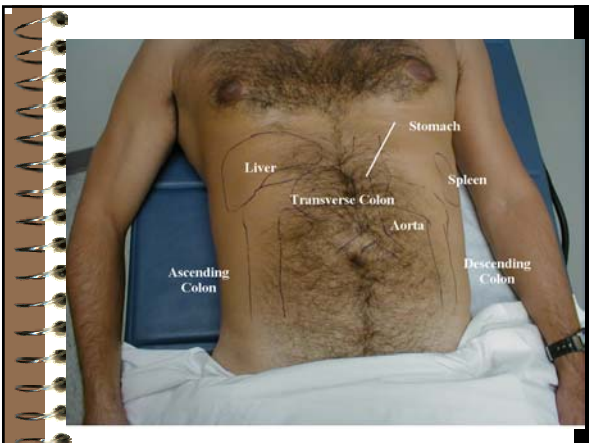
TIME NOW FOR SOME APPLICATION.

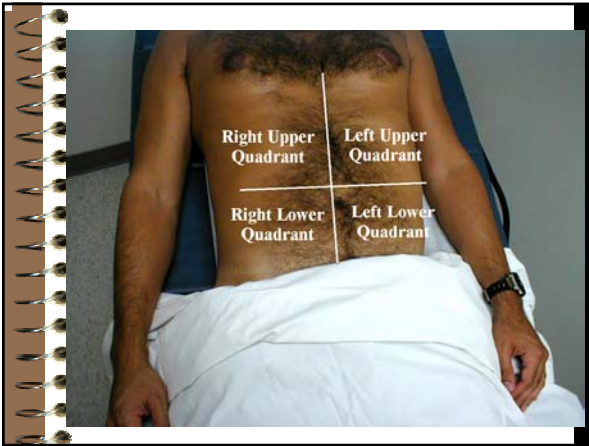
CASE 1. A 19-year-old female presents to the ER with severe right lower quadrant (RLQ) pain, fever to 38.7° C, rebound tenderness, and guarding. Her WBC is 21,000 with 80% neutrophils. The patient's pain initially began in the periumbilical region.

Dx: Perforated appendicitis, community-acquired

DEFINITIONS

- RLQ pain suggests appendix; LUQ suggests pancreas, RUQ suggests liver or gall bladder
- Rebound tenderness: pain felt when pressure applied to the abdomen is suddenly released
- Guarding: abdominal wall muscle spasm (voluntary or involuntary) that acts to protect inflamed abdominal viscera from pressure





CASE 1: BUGS AND DRUGS

- **Most likely pathogens**
 - Enteric Gram-negative bacilli
 - Bowel anaerobes
- **Patient will require surgery**
- **Drugs of choice**
 - Ampicillin/sulbactam (Unasyn)
 - Piperacillin/tazobactam (using the non-*Pseudomonas* dose)
 - Ertapenem
 - Is cefotetan monotherapy an option?

CASE 2. A 63-year-old female with metastatic ovarian cancer receiving radiation and chemotherapy develops fever, chills, and decreased alertness. She has had left lower quadrant pain for the past 24 hours. The patient is penicillin-allergic by history.

Dx: Diverticulitis, possibly ruptured

DEFINITIONS

A diverticulum is a pouch formed by protrusion (herniation) of the mucosa of the intestine through the muscular layers of the bowel wall. Diverticula can be clogged with fecal or other material and become infected (this is diverticulitis).

They can also rupture, resulting in secondary peritonitis.

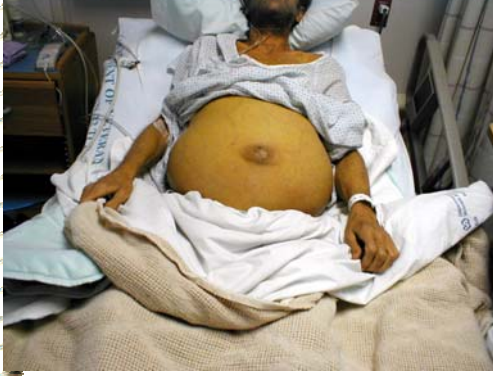CASE 2: BUGS AND DRUGS

- Possible pathogens
 - Enteric Gram-negative bacilli, including the more resistant genera
 - *Pseudomonas aeruginosa*
 - Bowel anaerobes
 - *Enterococcus*
- Possible treatments (how does the allergy figure in?)
 - Imipenem/cilastatin or meropenem
 - High-dose piperacillin/tazobactam
 - Aztreonam/clindamycin/vancomycin

CASE 3. A 67-year-old man with alcoholic liver cirrhosis, ascites, and encephalopathy is brought to the ER because of nausea, vomiting, severe abdominal pain, and altered mental status. Physical examination reveals fever, tachypnea, and a distended abdomen with positive guarding. CBC indicates leukocytosis with a left shift. Paracentesis is positive for numerous white cells and Gram-negative bacilli, coliform-like.

Dx: Spontaneous bacterial peritonitis (primary peritonitis)

Ascites
(abnormal fluid collection in the peritoneal cavity)



CASE 3: BUGS AND DRUGS

- **Most likely pathogens (just one!)**
 - Enteric Gram-negative bacilli, most likely *E. coli*
 - Anaerobes should not be an issue
- **No surgery!**
- **Drug of choice**
 - Ceftriaxone
 - Cefotaxime
 - Levofloxacin in allergic patients
- **Prevention of future episodes**
 - Weekly ciprofloxacin

CASE 4. A 60-year-old male with poorly controlled diabetes is admitted with high fever and elevated WBC. His admission blood glucose is 530 (normal BG is 60-110). The patient's right foot is hot, swollen, and foul-smelling, and a sore under the 5th metatarsal joint is draining pus.

Dx: Diabetic foot infection

CASE 4: BUGS AND DRUGS

- **Most likely pathogens**
 - Just about anything: enteric flora, anaerobes, *P. aeruginosa*, Gram-positive aerobes
- **Drugs of choice**
 - Piperacillin/tazobactam
 - Ticarcillin/clavulanic acid
- **What is the goal of treatment?**
