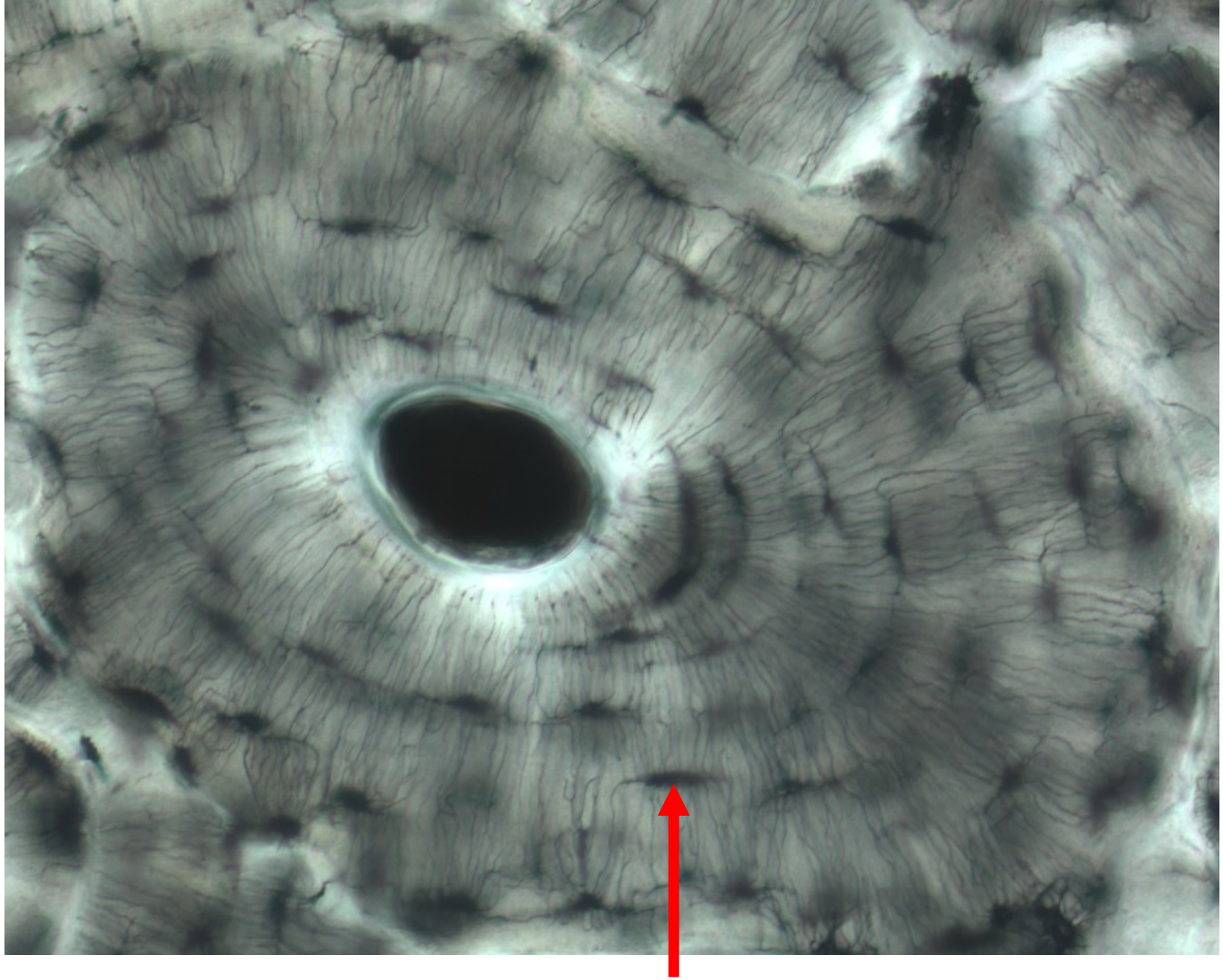
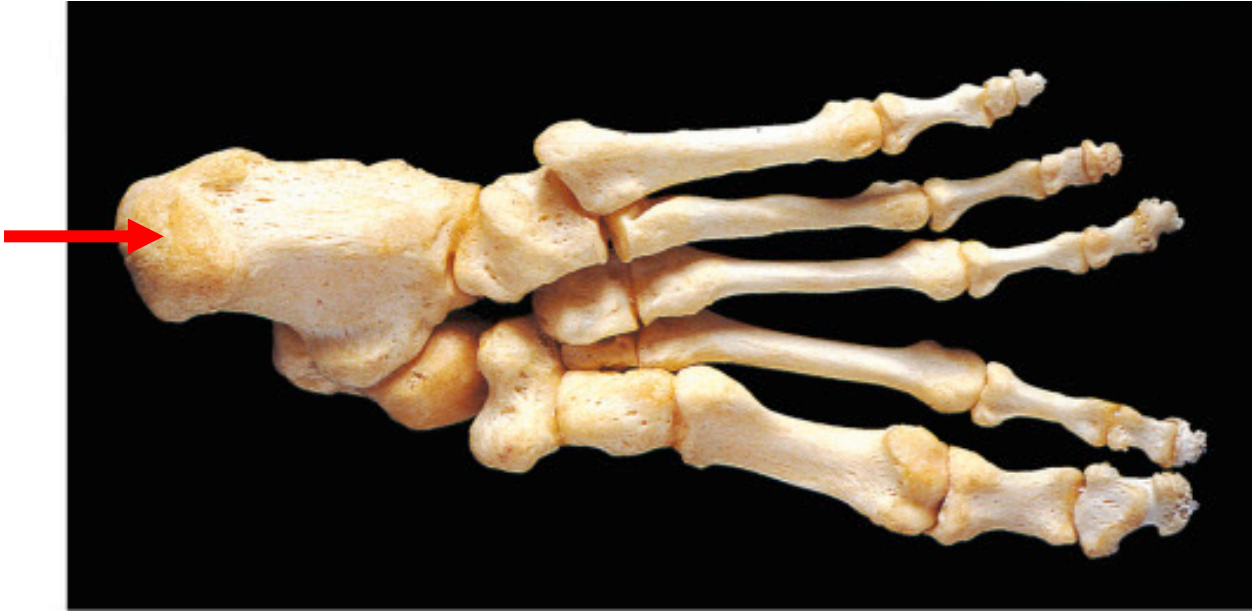


Quiz Section Test 3-AA
Answers are given in red.



1. Name the cell that would be found in the space indicated by the arrow.


osteocyte



2. Name the bone indicated by the arrow.

calcaneus

anterior view

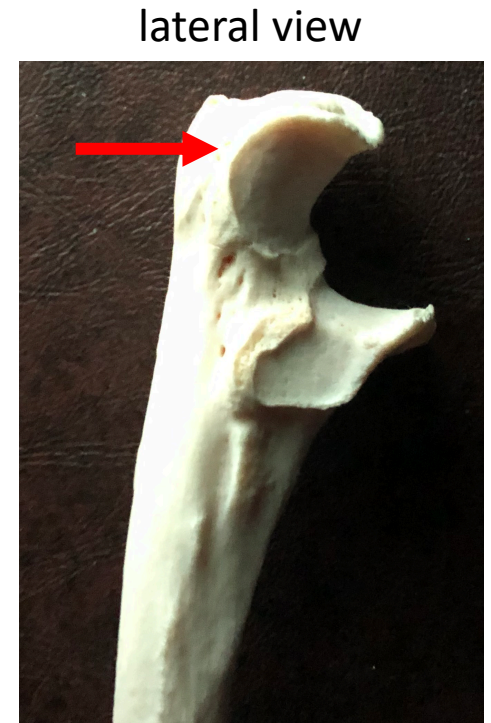

anterior and superior view

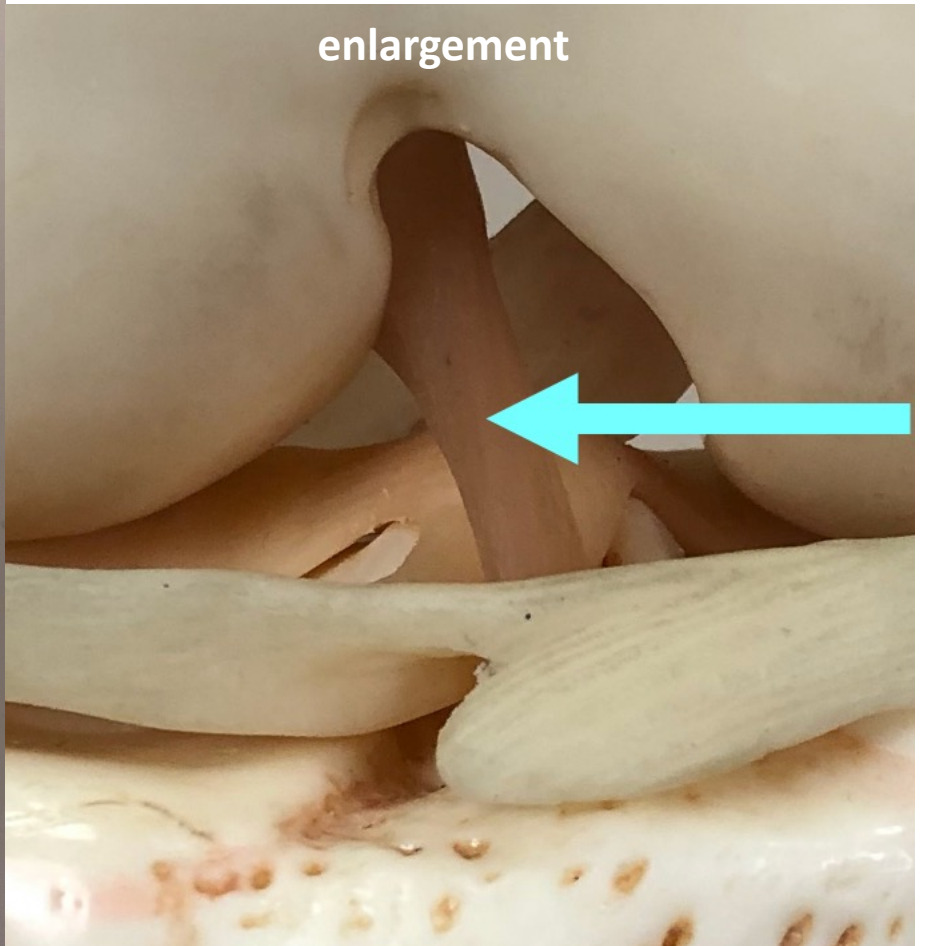
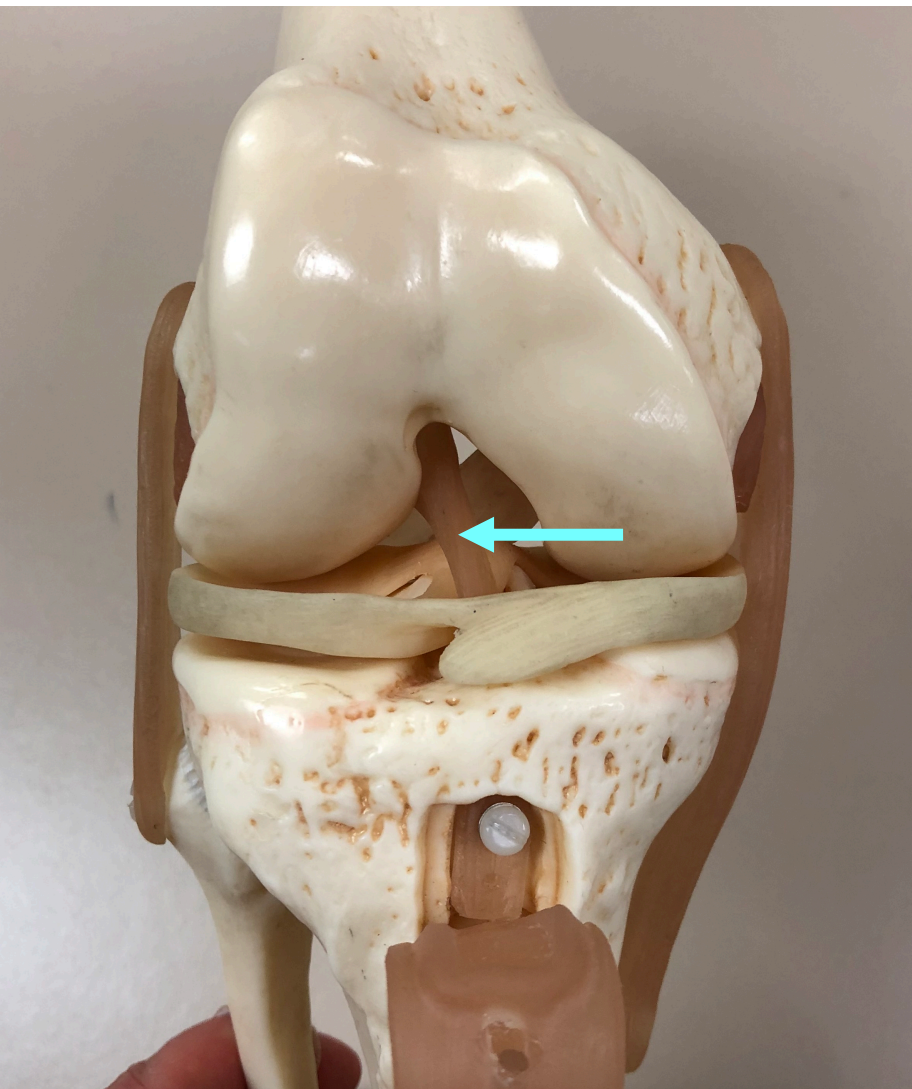


3. Name the rough projection indicated by the arrow.

tibial tuberosity



4. Which of the following is indicated by the arrow?
- a. radial tuberosity
 - b. olecranon fossa
 - c. greater trochanter
 - d. olecranon process
 - e. lateral malleolus



5. Name the structure indicated by the arrow.

anterior cruciate ligament