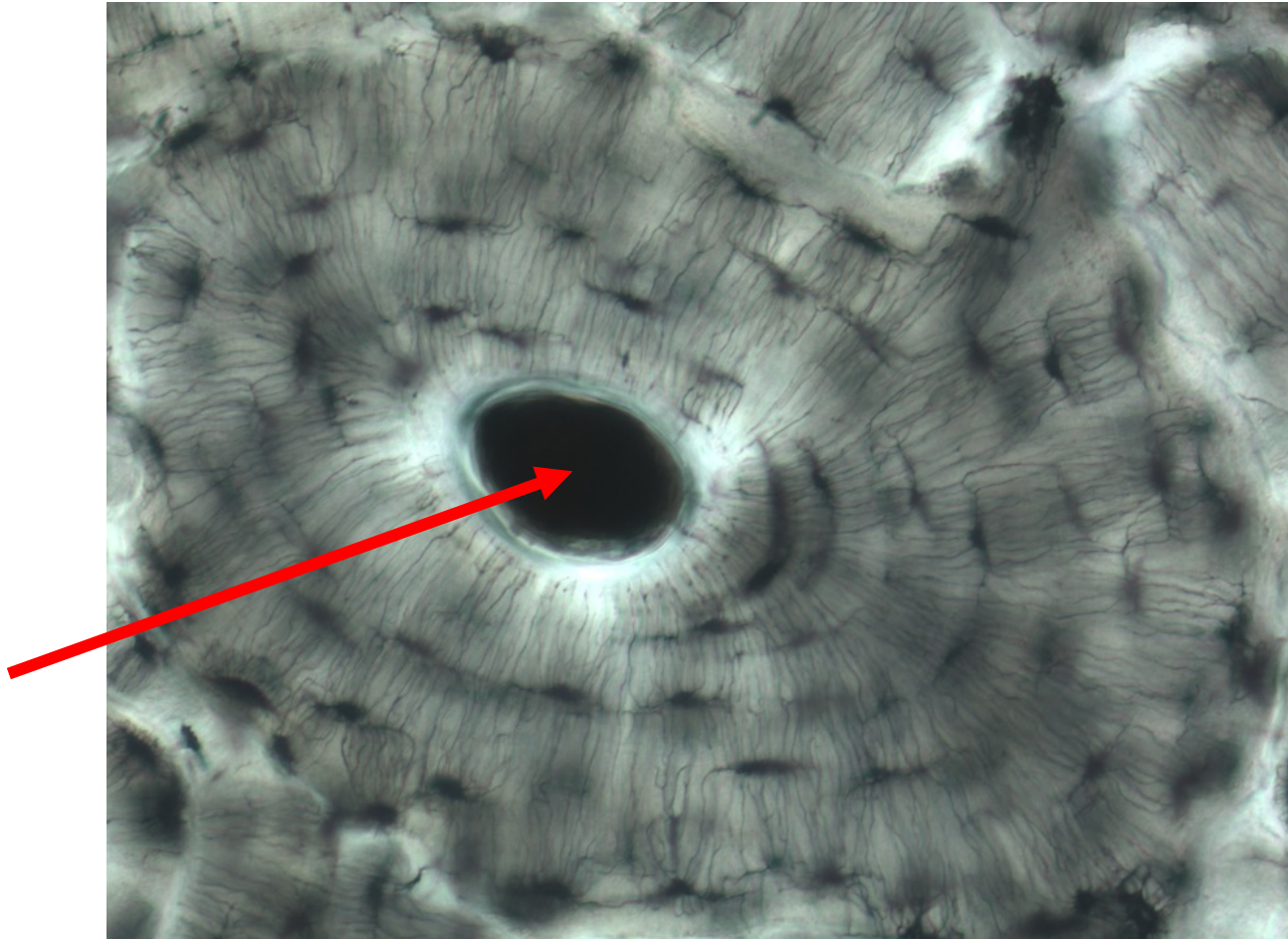


**Quiz Section Test 3-AB**  
**Answers are given in red.**



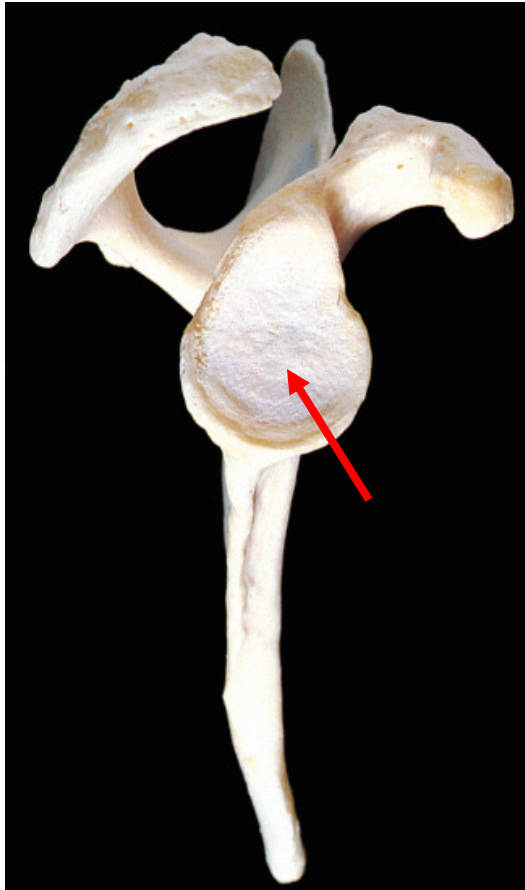
1. Which of the following is indicated by the arrow?
  - a. osteocyte
  - b. lamella
  - c. lacuna
  - d. Haversian canal**
  - e. chondrocyte



2. Name the bone shown.

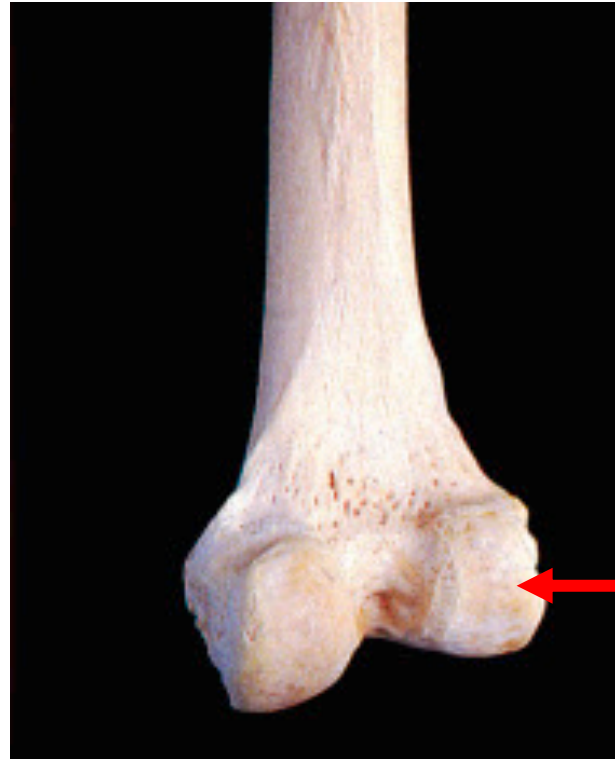ulna

lateral view



3. Name the specific part of the bone indicated by the arrow.

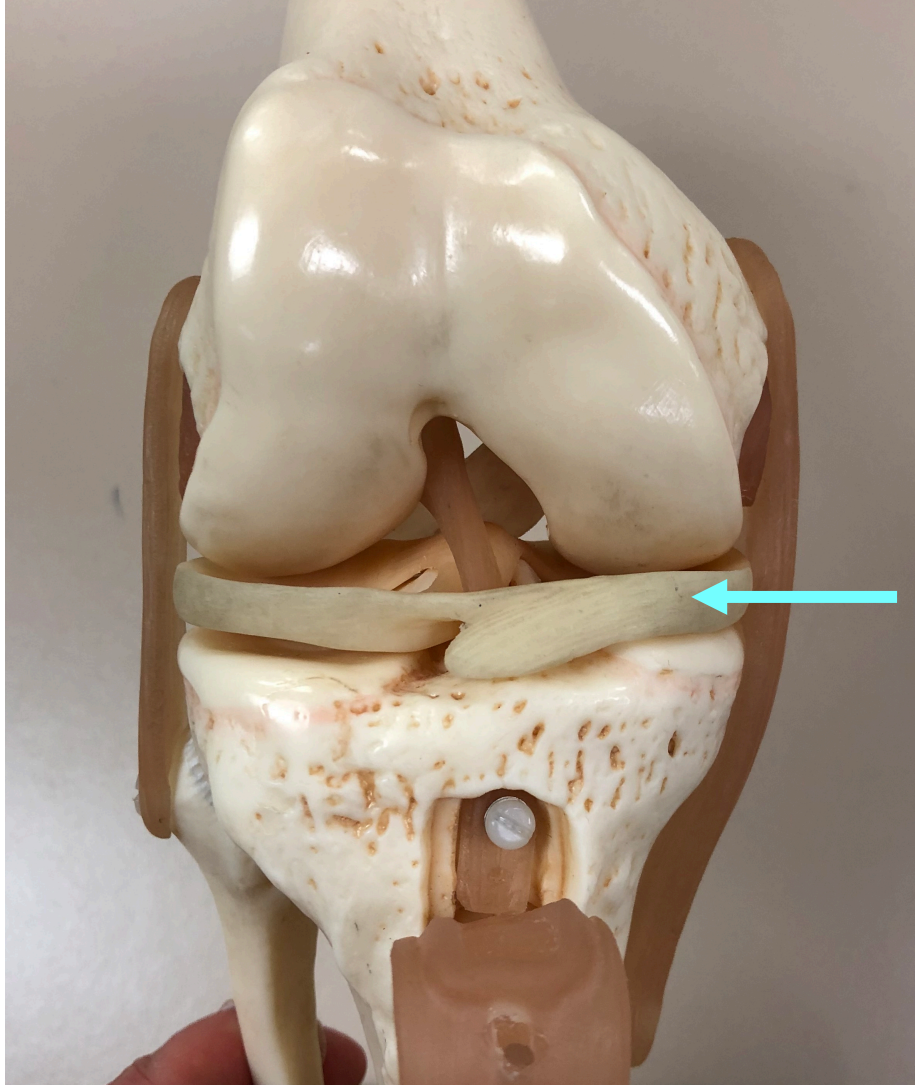**glenoid cavity**



4. Name the specific part of the bone shown by the arrow.

**lateral condyle**





5. Name the structure indicated by the arrow.

**medial meniscus**