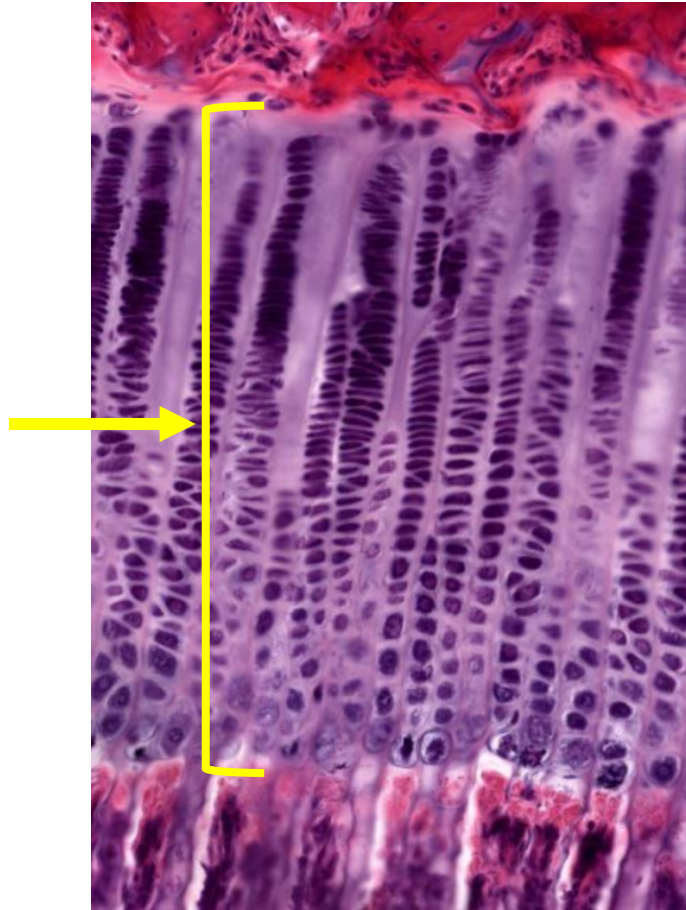
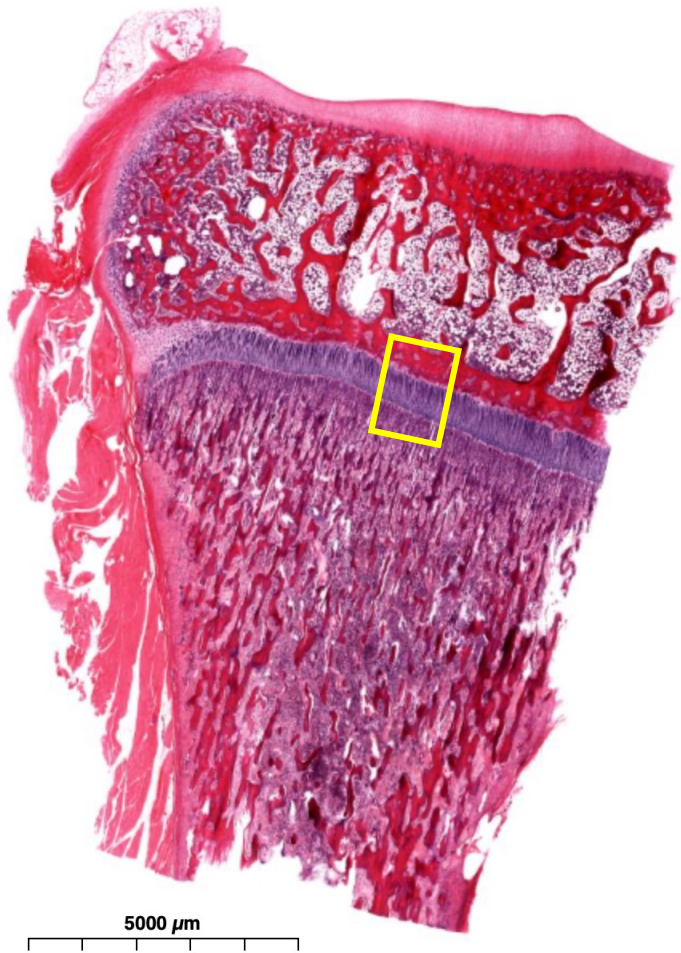
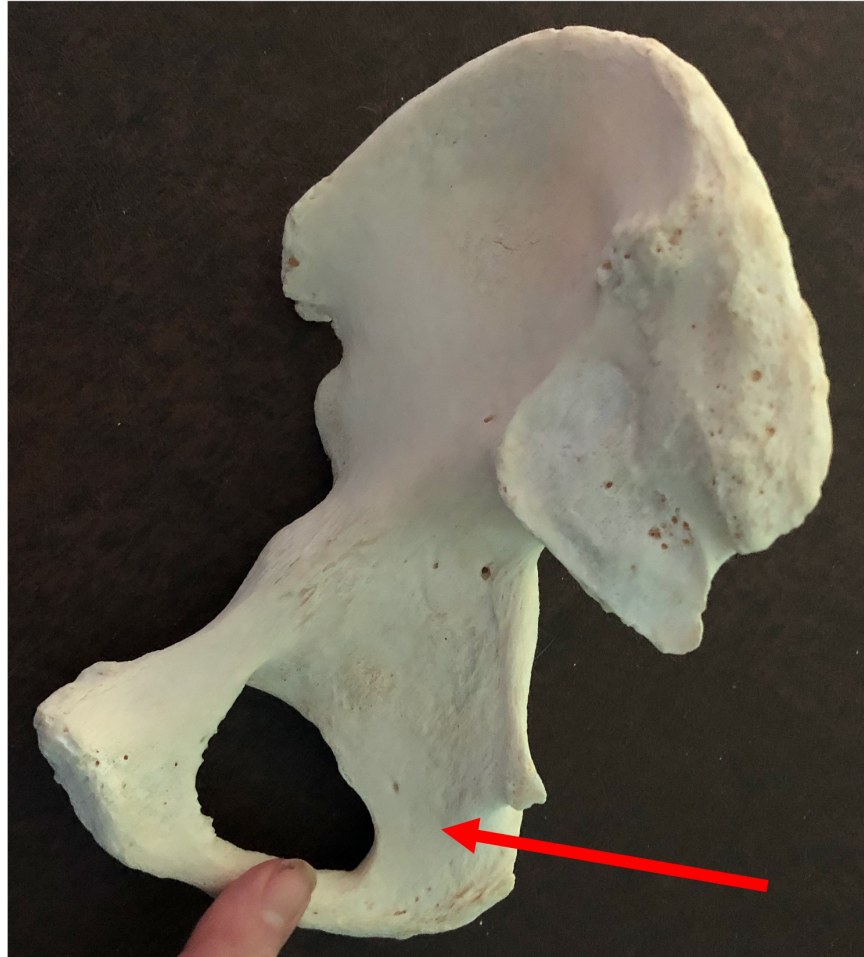


Quiz Section Test 3-AC
Answers are given in red.



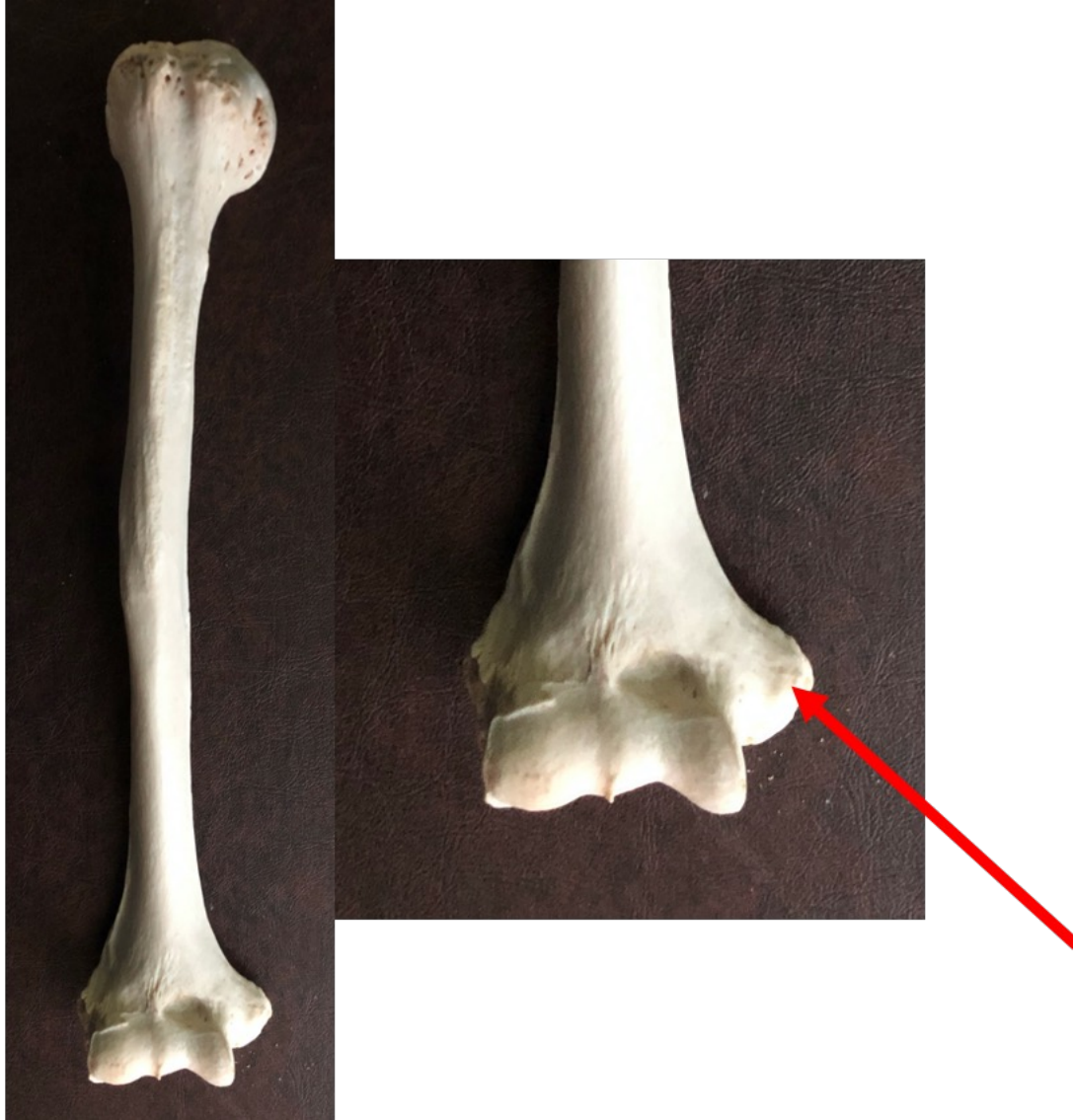1. Name the type of cell found in the epiphyseal growth plate.

chondrocyte



2. Name the specific bone indicated by the arrow.

ischium

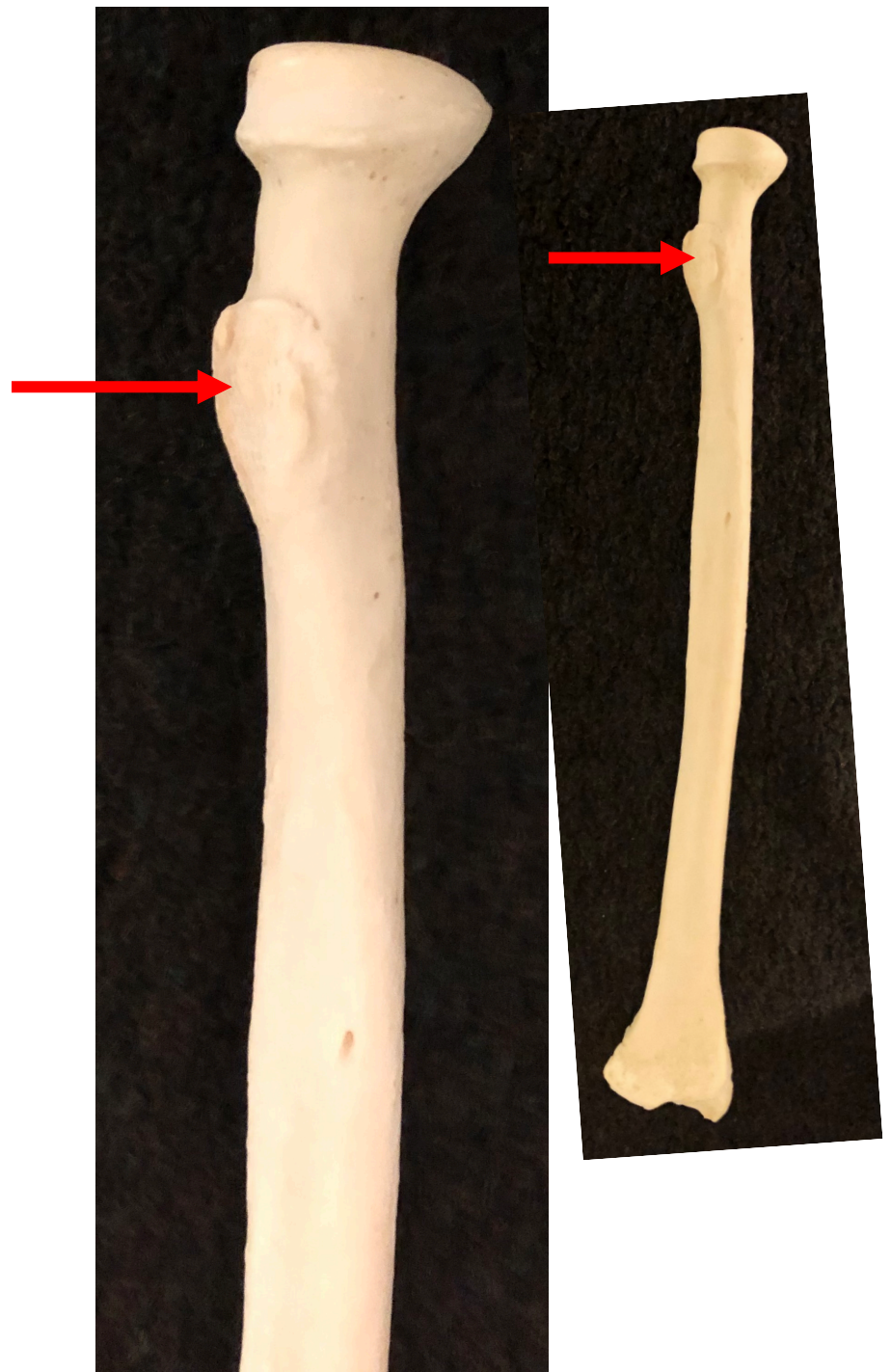


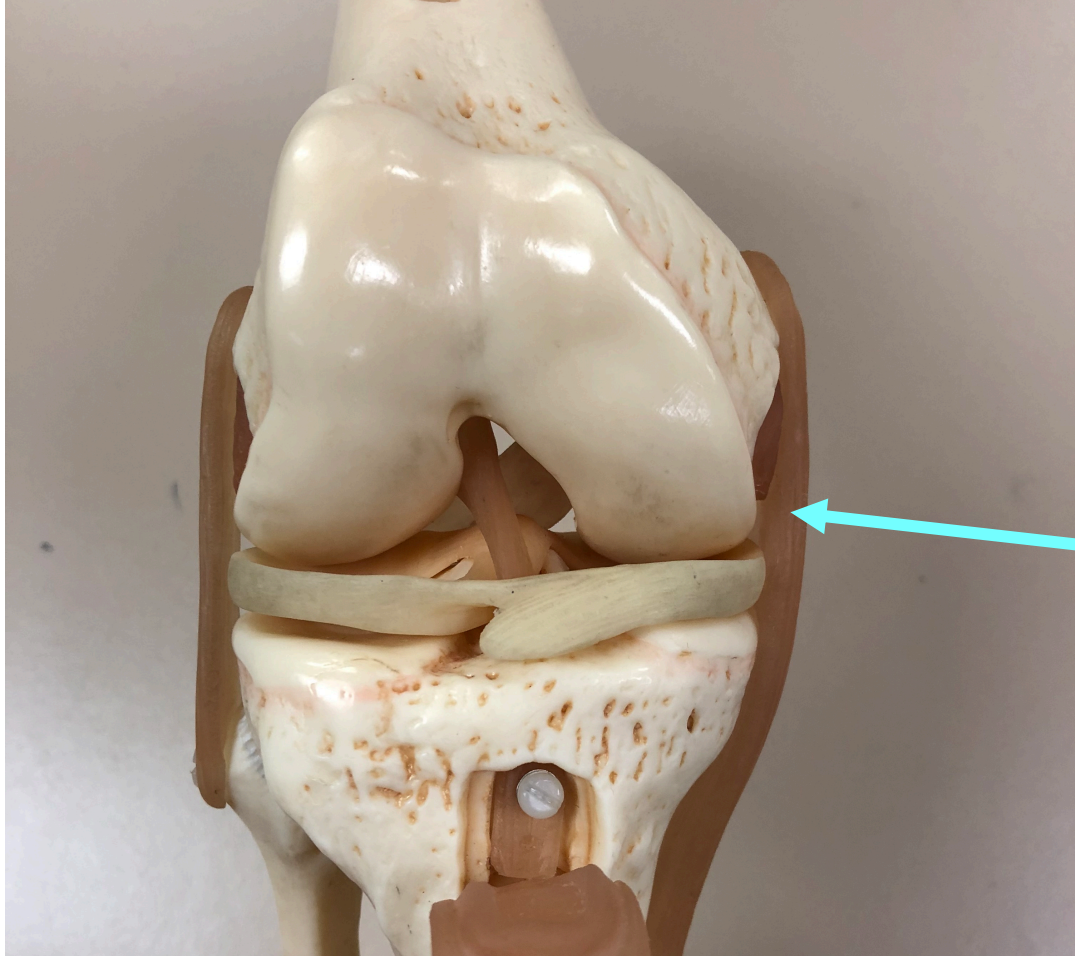
3. Name the specific part of the bone shown by the arrow.

medial epicondyle

4. Which of the following is indicated by the arrow?

- a. deltoid tuberosity
- b. tibial tuberosity
- c. radial tuberosity
- d. olecranon process
- e. greater trochanter





5. Name the specific structure indicated by the arrow.

tibial collateral ligament