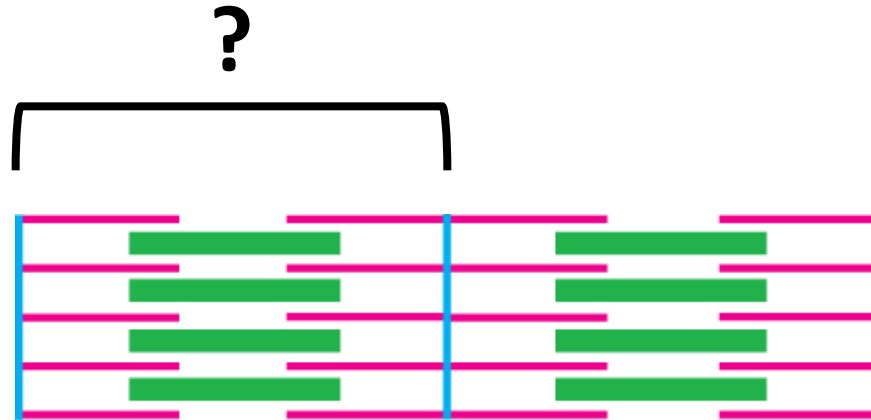
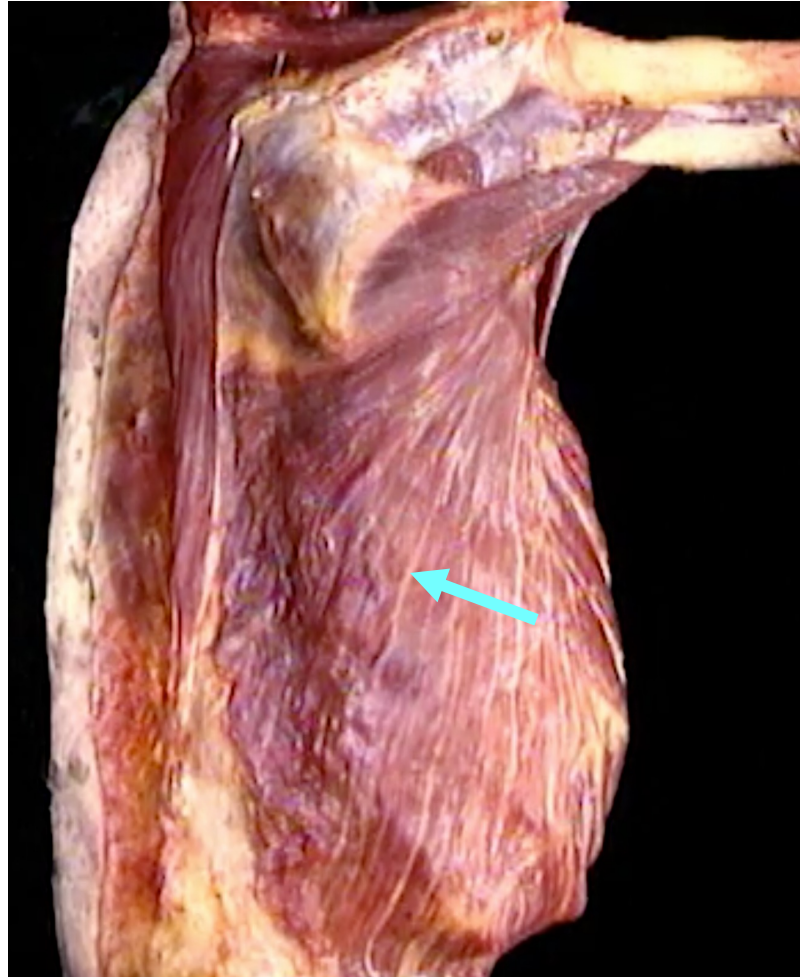


Quiz Section Test 4-AC
Answers are given in red.




1. What is the term for the contractile unit in a myofibril?
sarcomere

posterolateral view



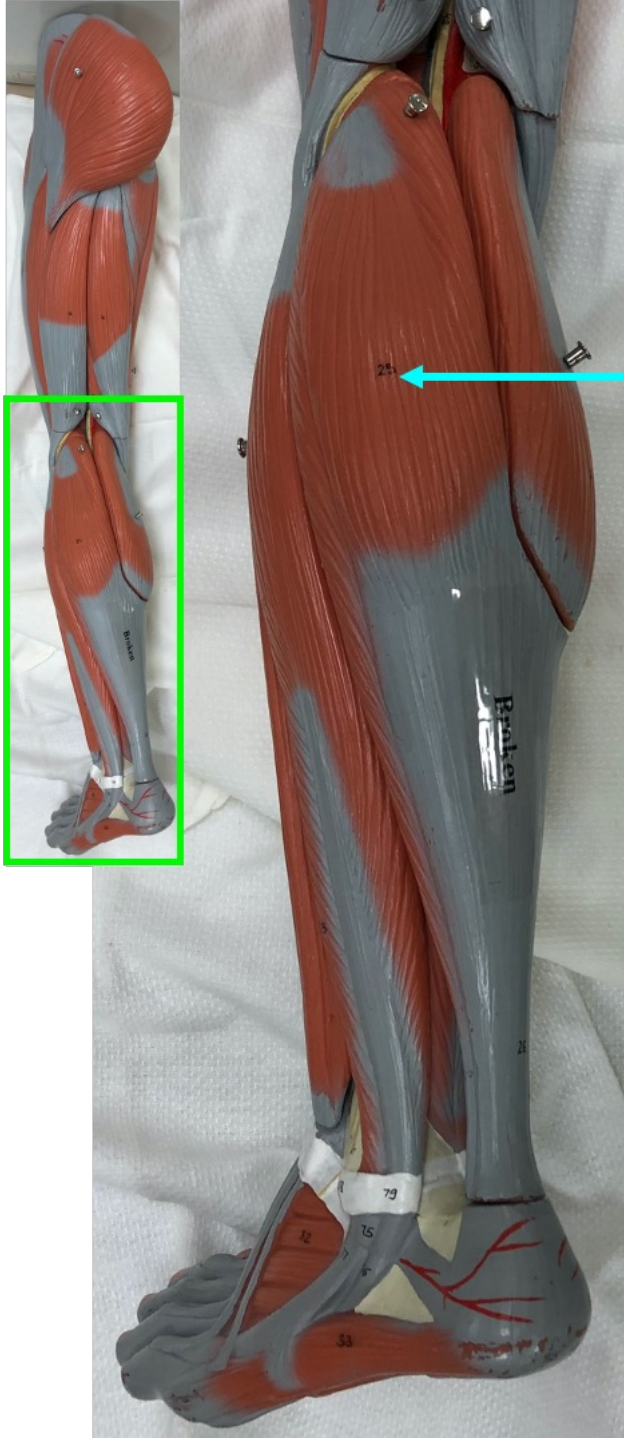
2. Name the muscle indicated by the arrow.

latissimus dorsi



3. What is the action of the muscle indicated by the arrow? Be sure to specify the joint at which this action is occurring.

extension at the wrist



4. Name the muscle indicated by the blue arrow.

gastrocnemius

5. Which of the following might be observed in a patient with an upper motor neuron disorder?

- a. weak or absent stretch reflex
- b. bradykinesia
- c. **hyperreflexia and hypertonia**
- d. resting tremor