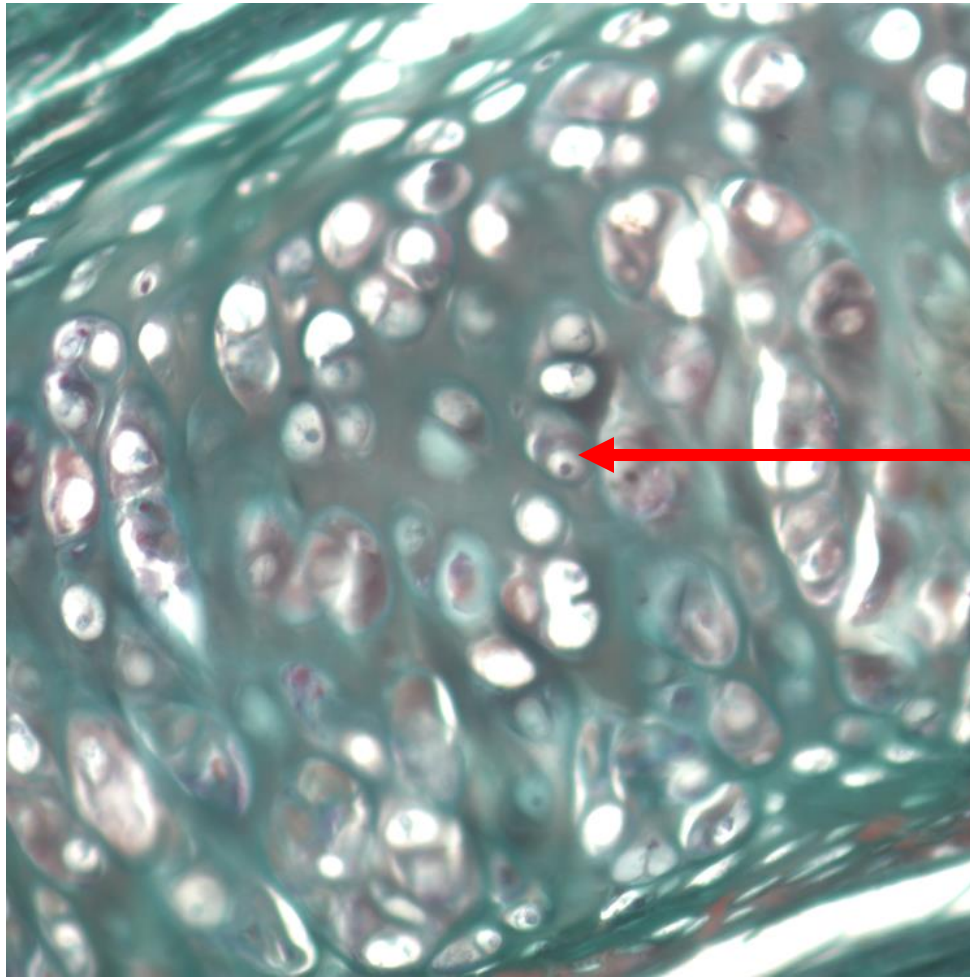




**Quiz Section Test 3-AA**  
**Answers are given in red.**



1. Name the cell indicated by the arrow.

**chondrocyte**

anterior view

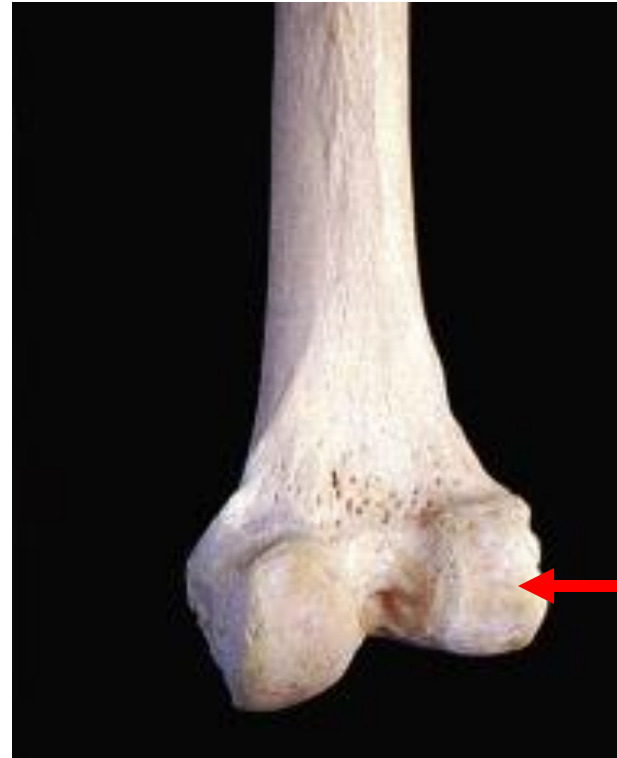

posterior view



2. Name the bone shown.

**humerus**

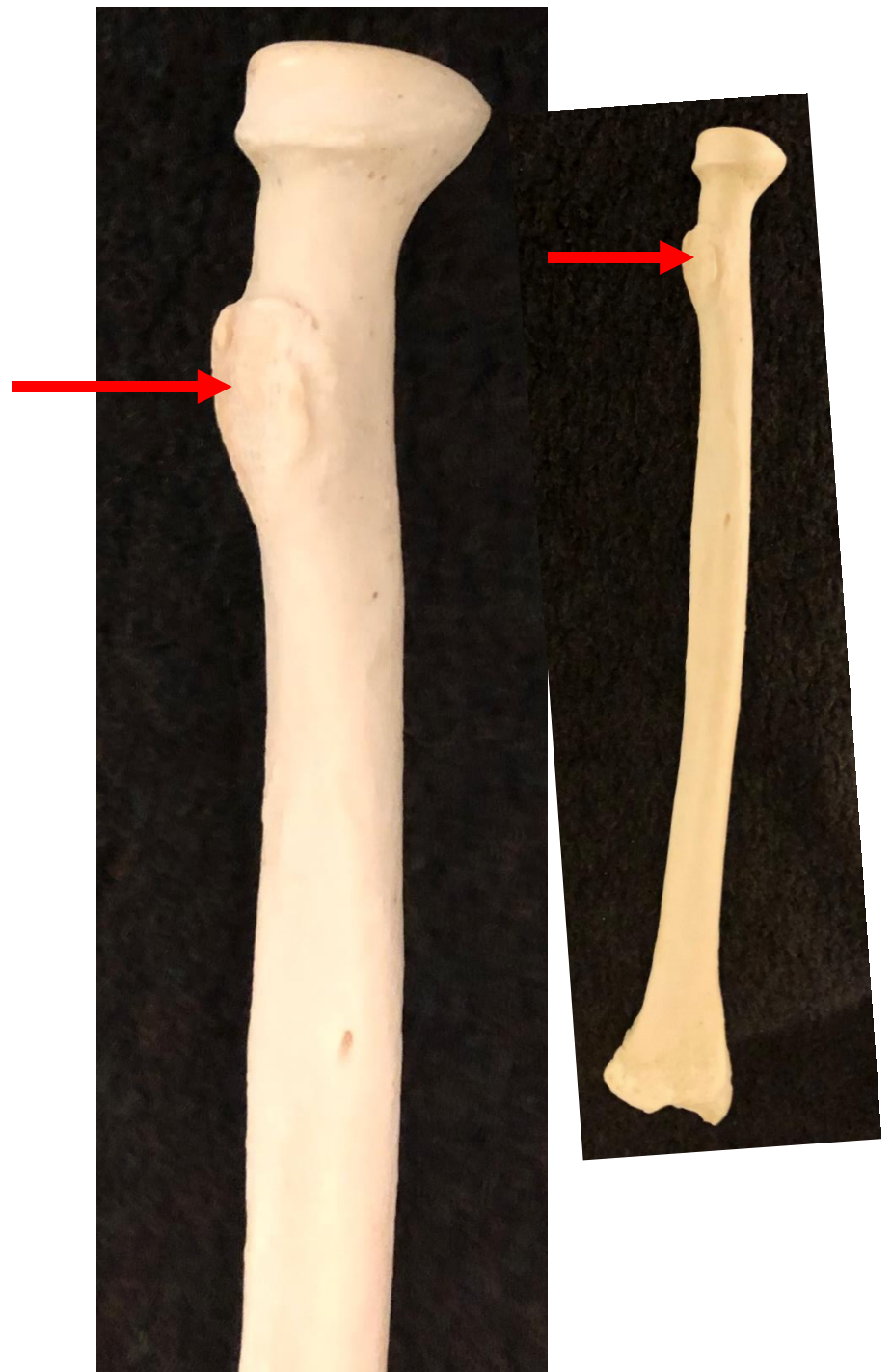


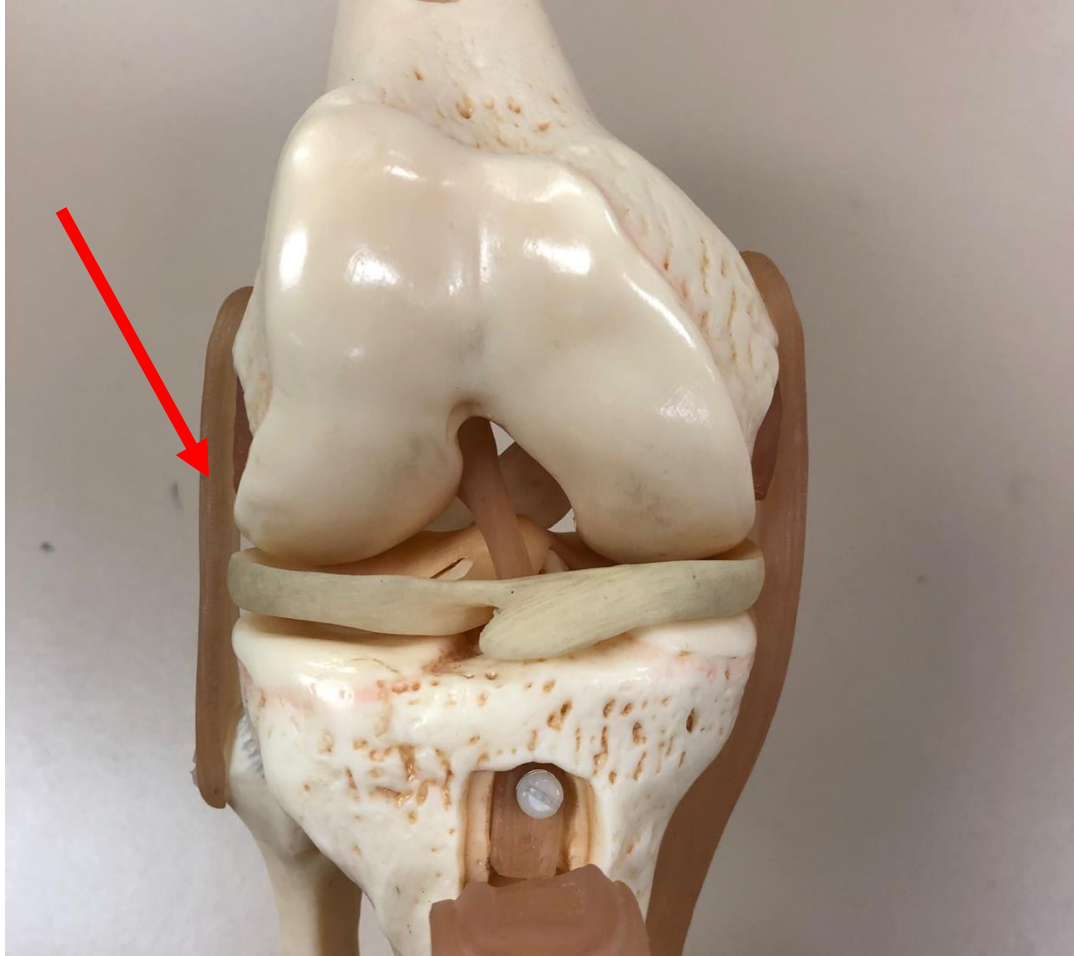3. Name the specific part of the bone shown by the arrow.

**lateral condyle**

4. Which of the following is indicated by the arrow?

- a. deltoid tuberosity
- b. tibial tuberosity
- c. **radial tuberosity**
- d. olecranon process
- e. greater trochanter





5. Name the structure indicated by the red arrow.

**fibular collateral ligament**