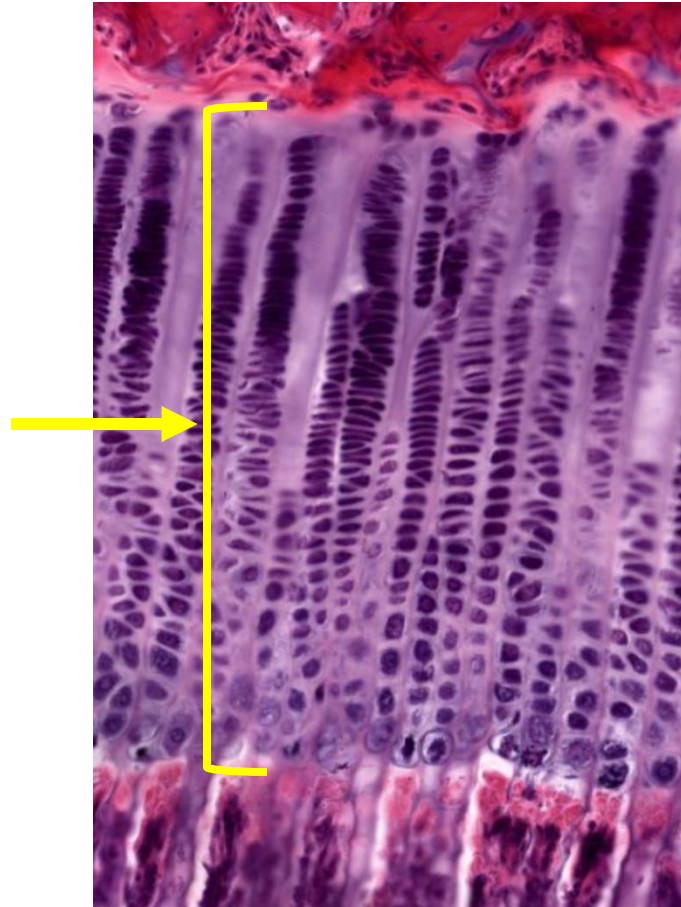
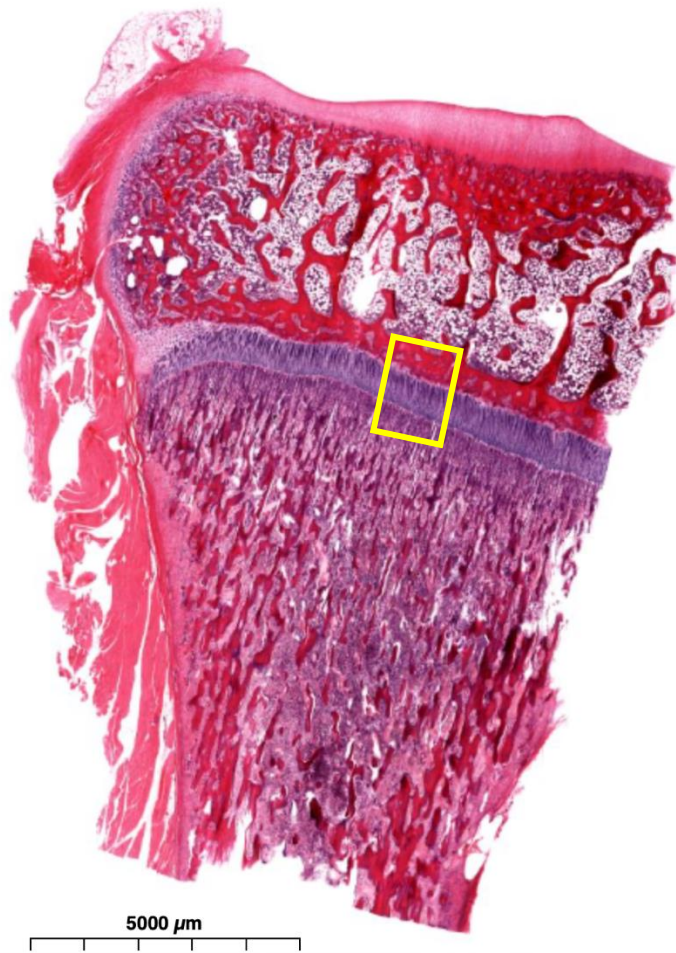


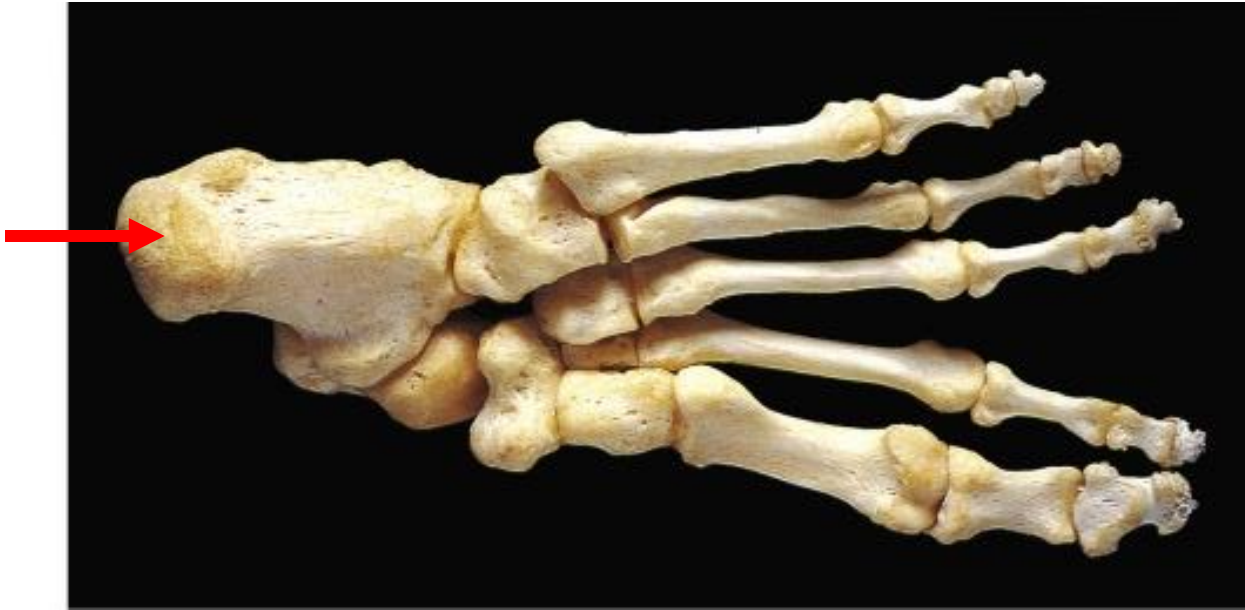Quiz Section Test 3-AC
Answers are given in red.





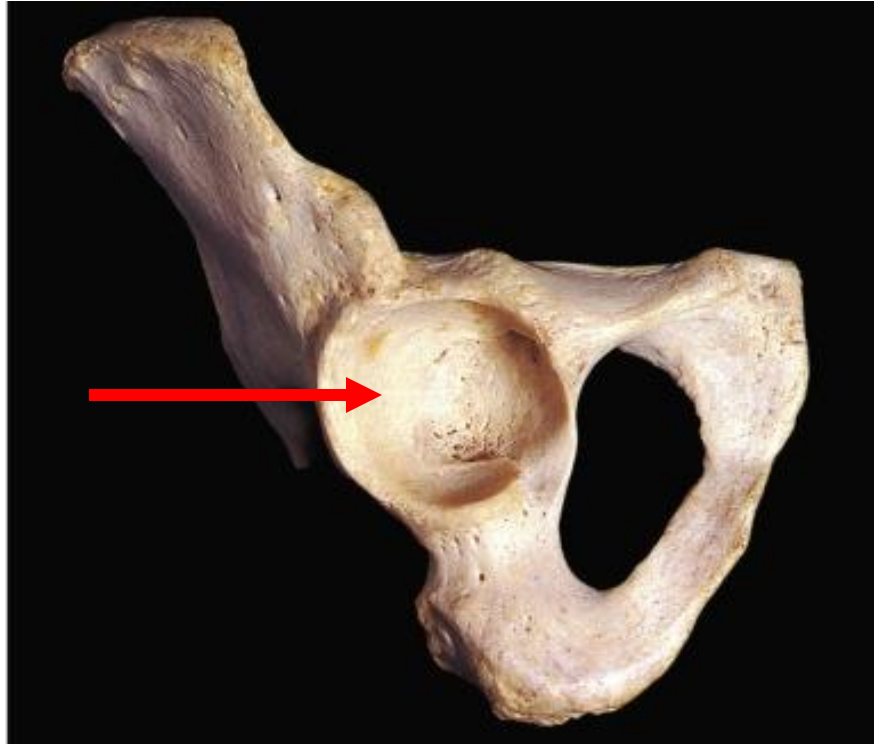1. Name the type of cell found in the epiphyseal growth plate.

chondrocyte



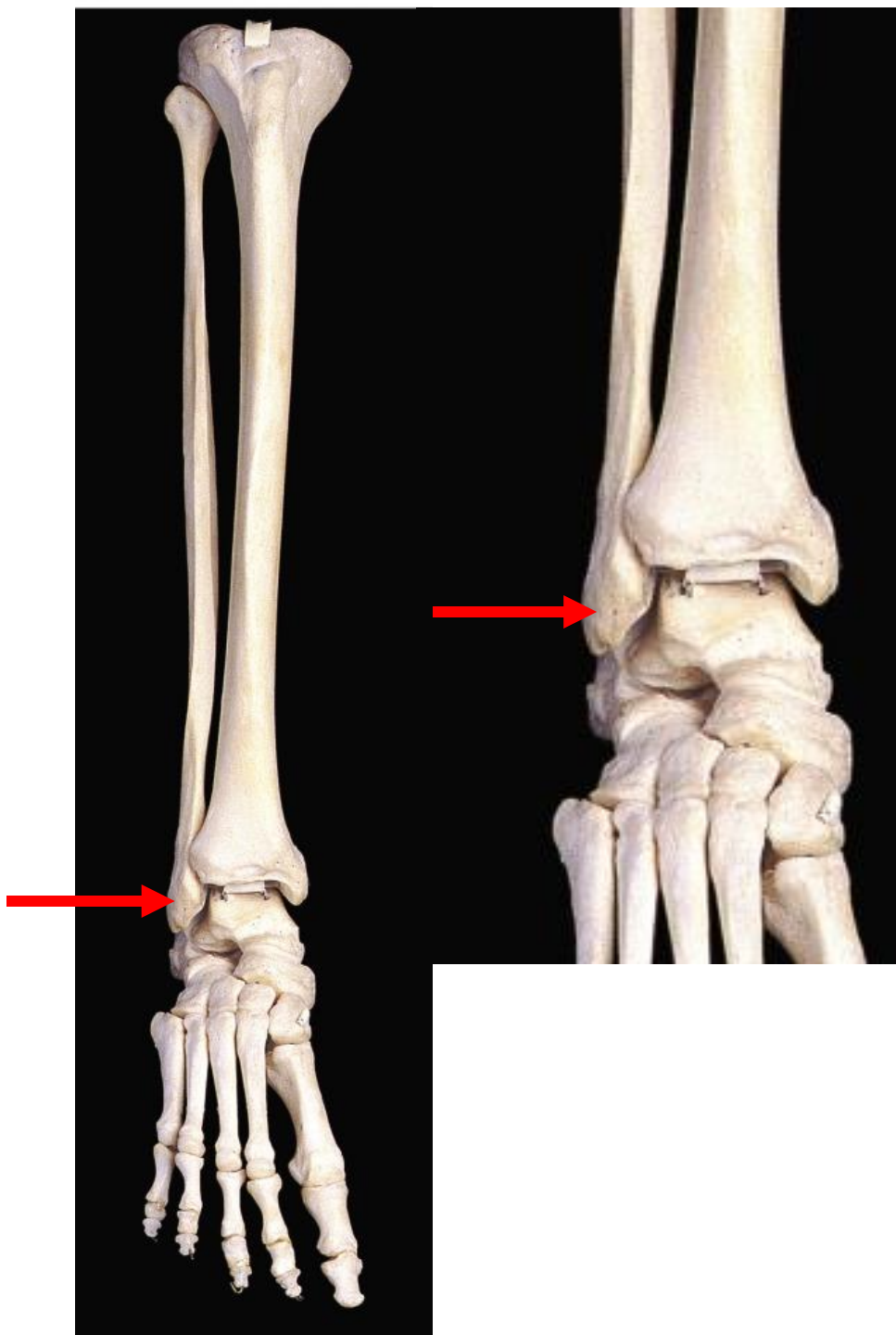
2. Name the bone indicated by the arrow.

calcaneus



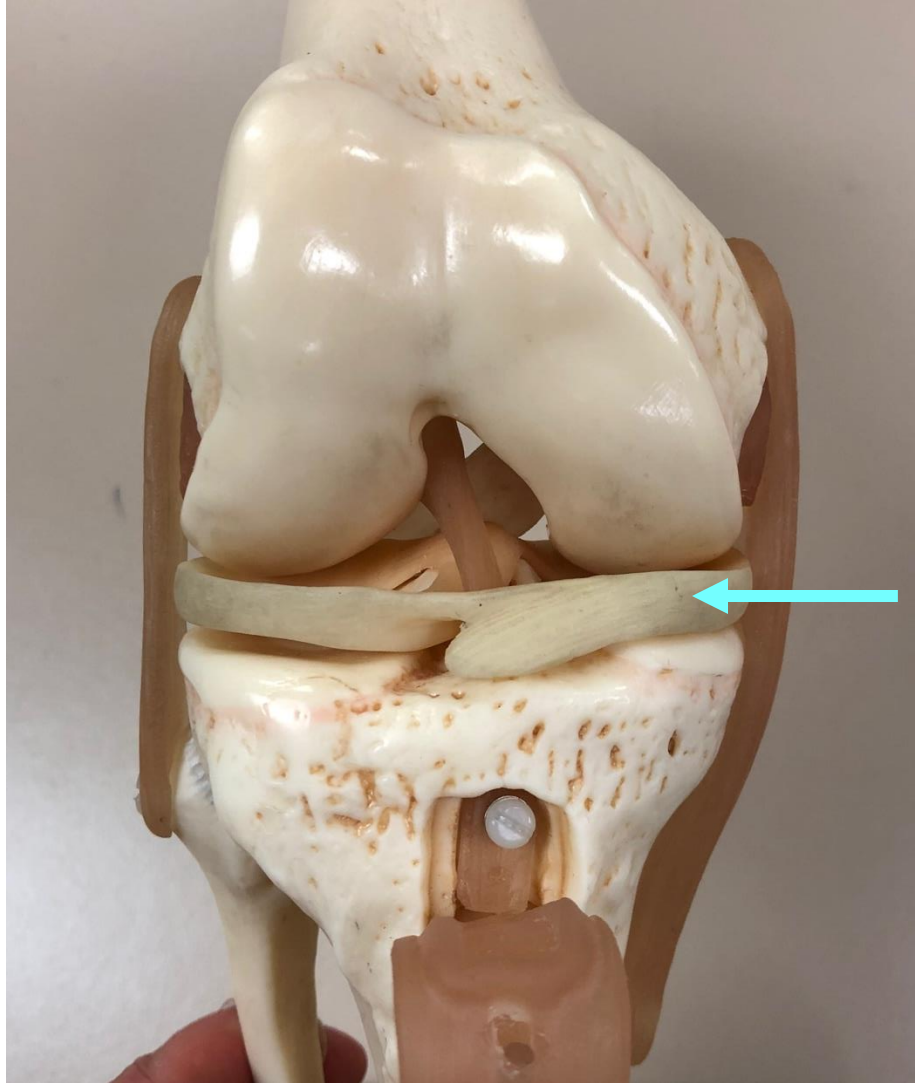
3. Name the specific part of the bone shown by the arrow.

acetabulum



4. Which of the following is shown by the arrow?

- a. medial malleolus
- b. medial condyle
- c. lateral condyle
- d. lateral epicondyle
- e. **lateral malleolus**



5. Name the structure indicated by the arrow.

medial meniscus