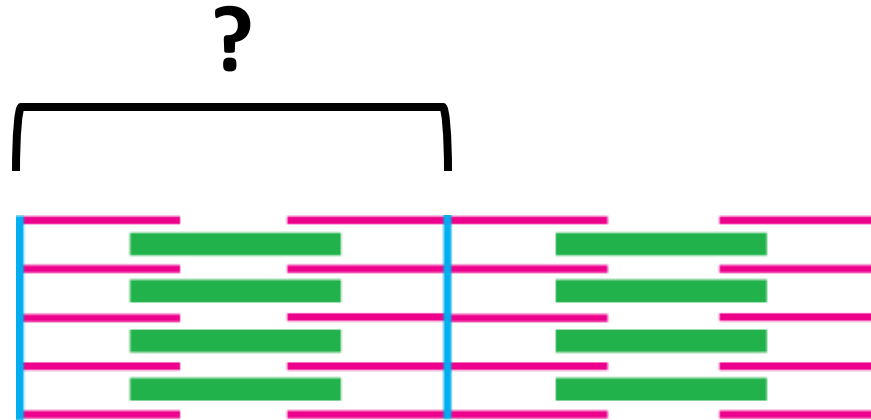


Quiz Section Test 4-AB
Answers are given in red.

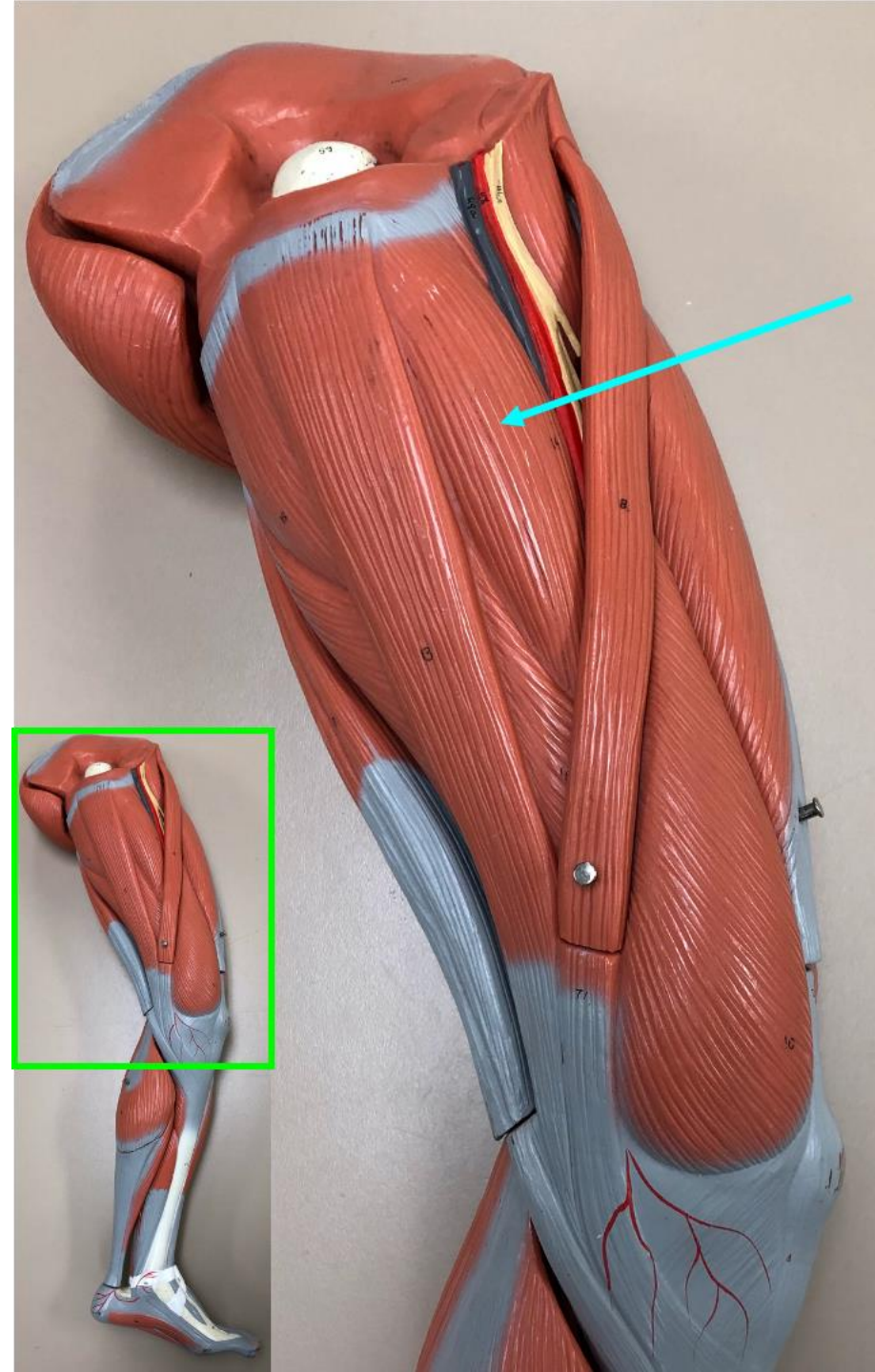


1. What is the term for the contractile unit in a myofibril?

sarcomere



2. Which of the following muscles is shown by the arrow?
- a. pronator teres
 - b. flexor carpi radialis
 - c. extensor carpi ulnaris
 - d. extensor carpi radialis**
 - e. brachioradialis



3. Which of the following is the action of the muscle indicated by the arrow?

- a. abduction of the thigh
- b. flexion of the thigh
- c. lateral rotation of the thigh
- d. medial rotation of the thigh
- e. **adduction of the thigh**



4. Name the muscle indicated by the arrow.

vastus lateralis

5. Which of the following might be observed in a patient with an upper motor neuron disorder?

- a. weak or absent stretch reflex
- b. bradykinesia
- c. **hyperreflexia and hypertonia**
- d. resting tremor