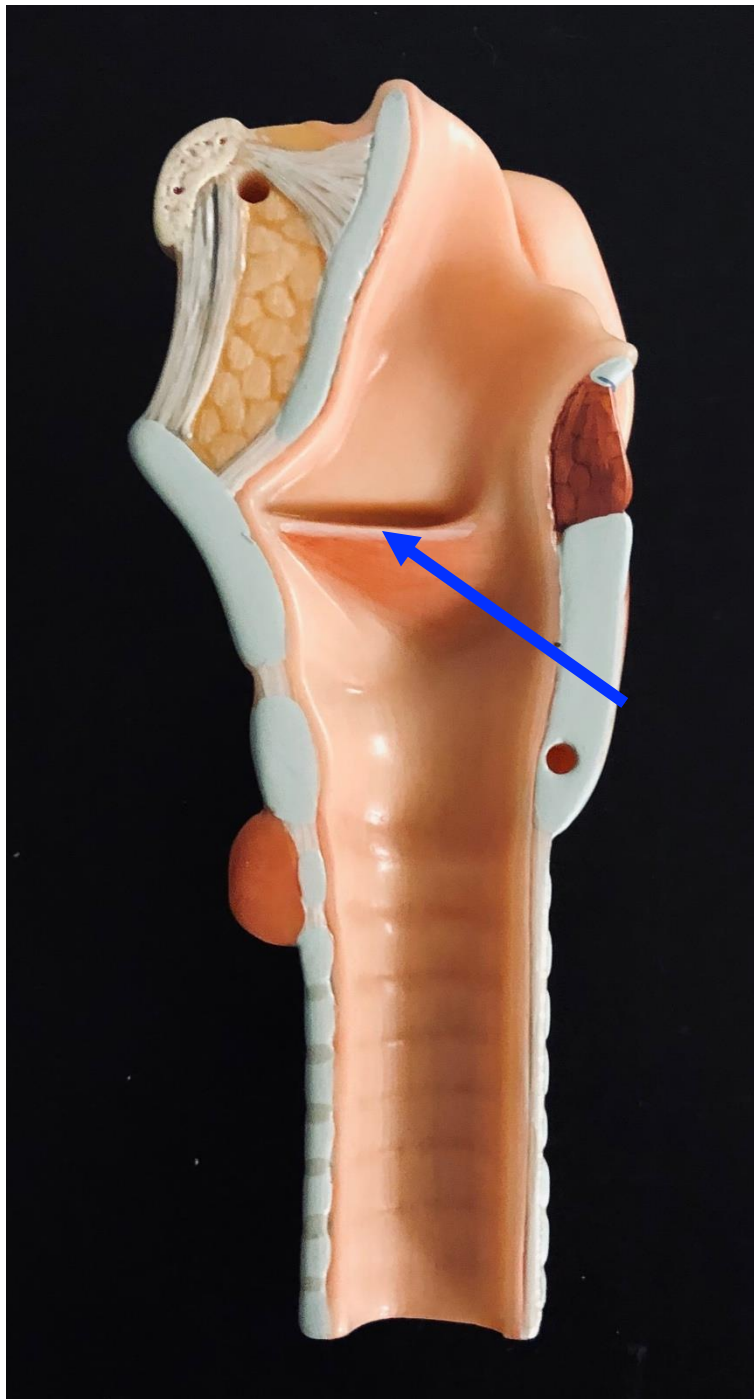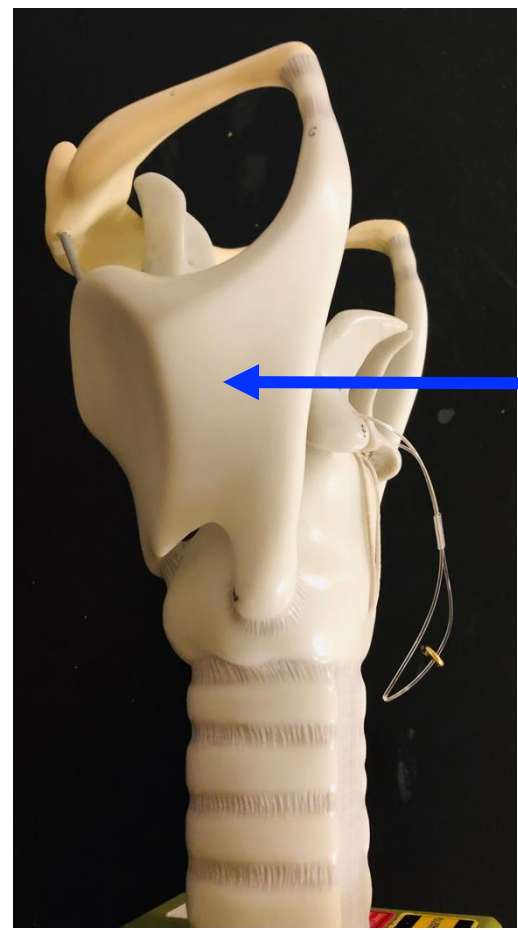
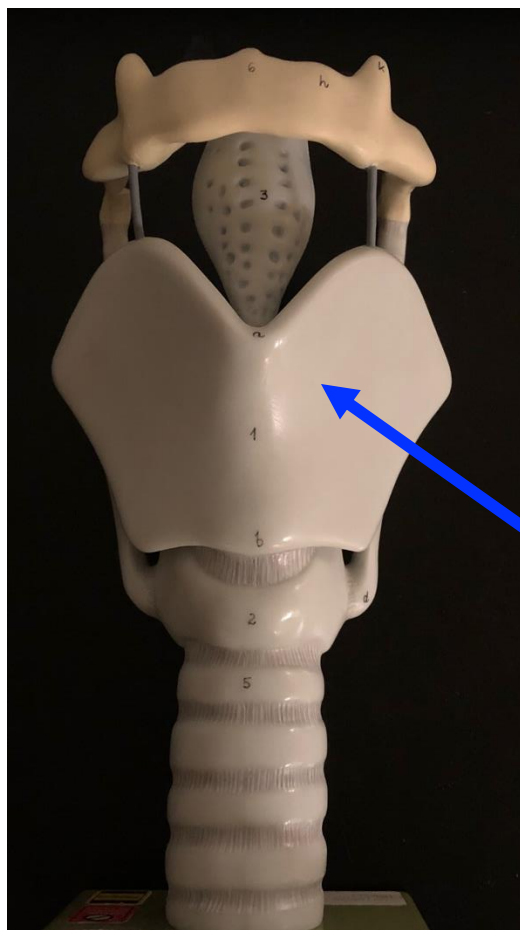


Quiz Section Test 2-AA
Answers are given in red.

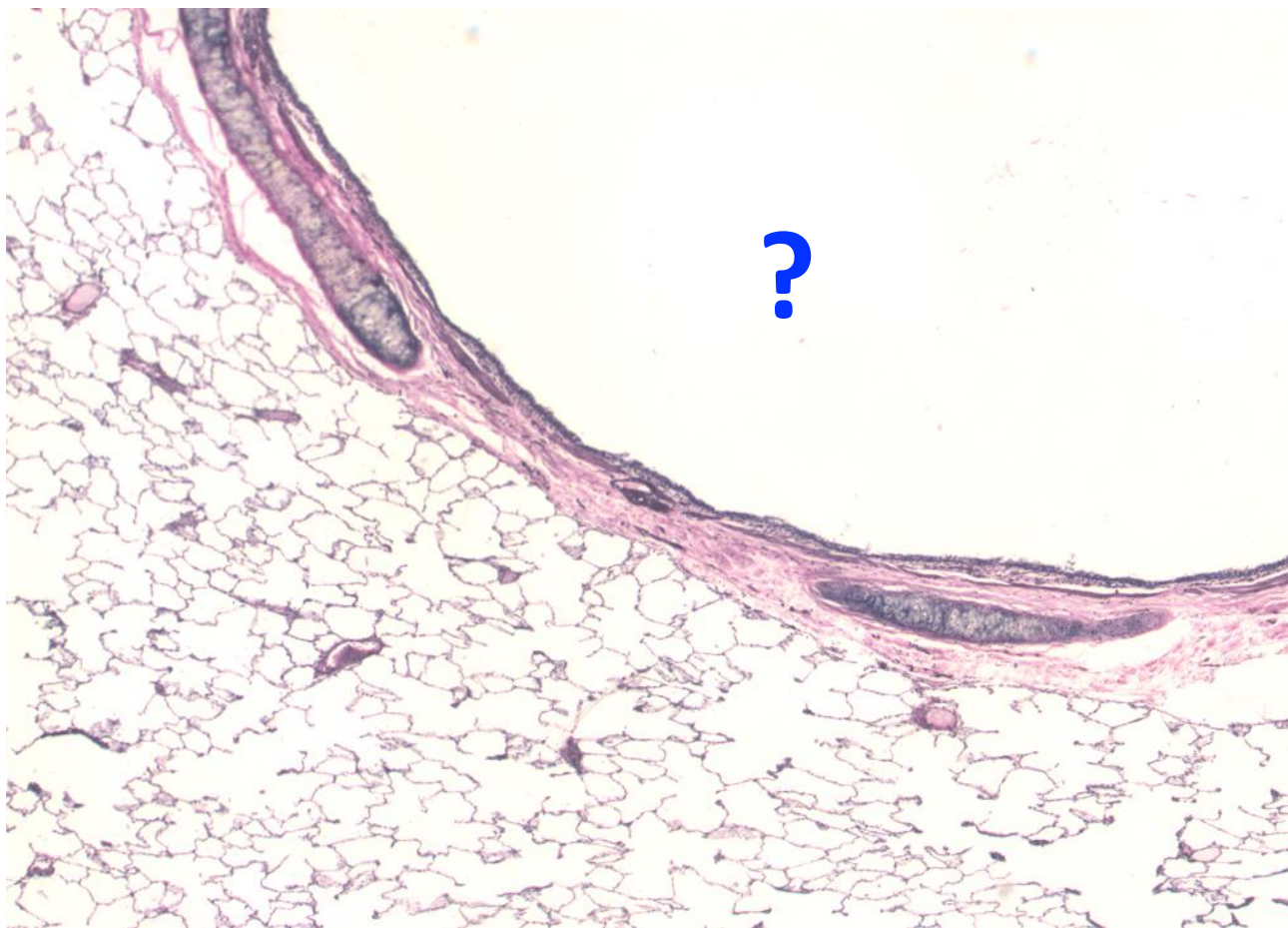

1. Name the structure indicated by the arrow.

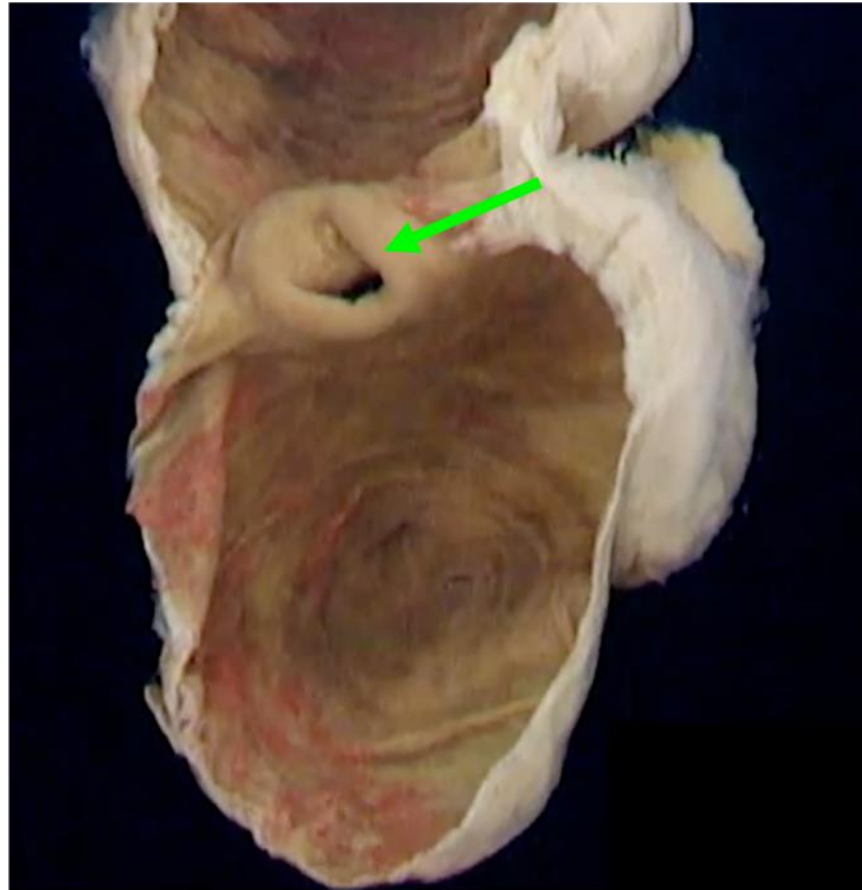
vocal fold



2. Which of the following is indicated by the arrow?
- a. hyoid bone
 - b. arytenoid cartilage
 - c. cricoid cartilage
 - d. glottis
 - e. **thyroid cartilage**



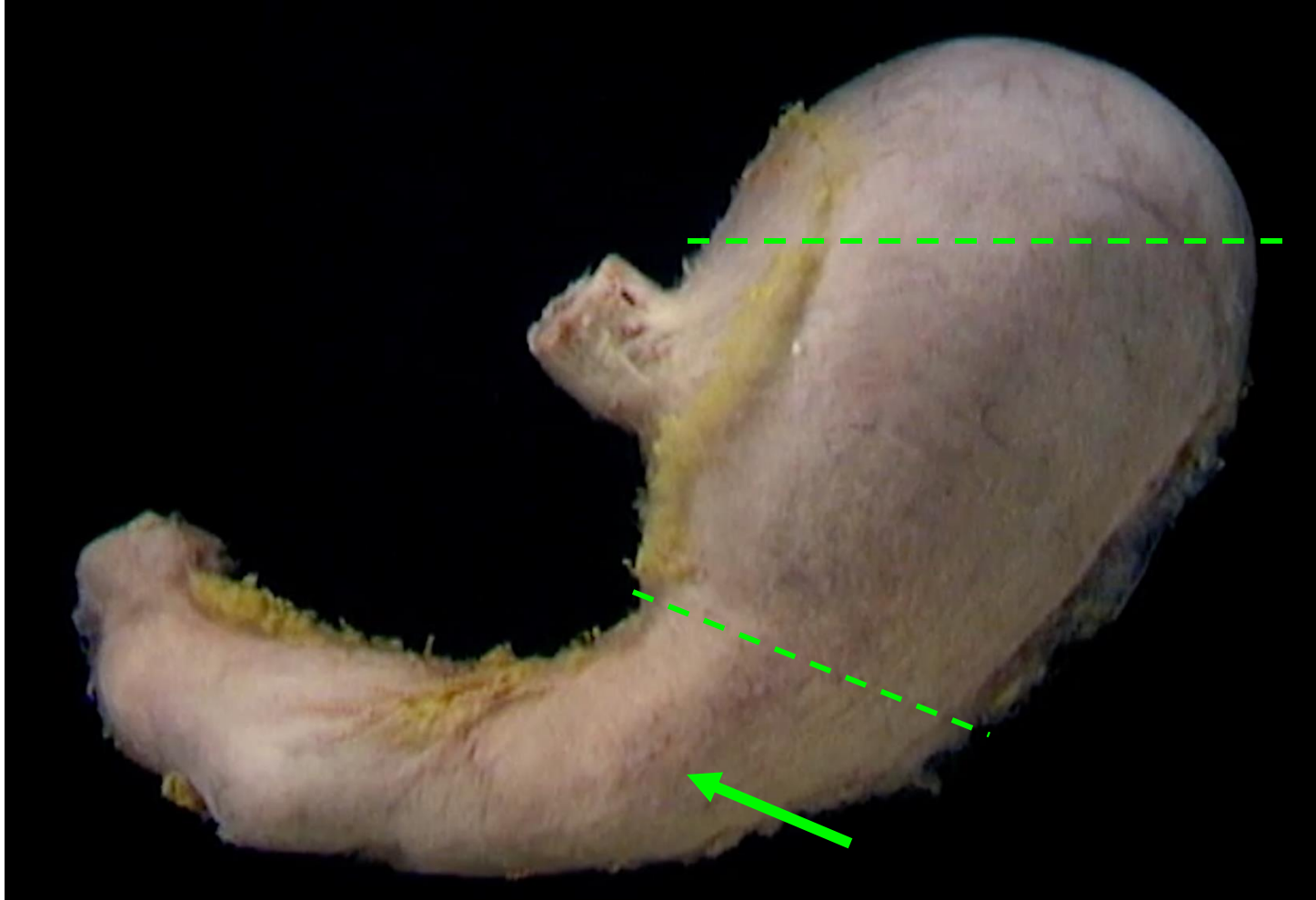
3. Which of the following is indicated by the question mark?
- a. alveolus
 - b. alveolar duct
 - c. **bronchus**
 - d. trachea
 - e. bronchiole



internal view of isolated cecum

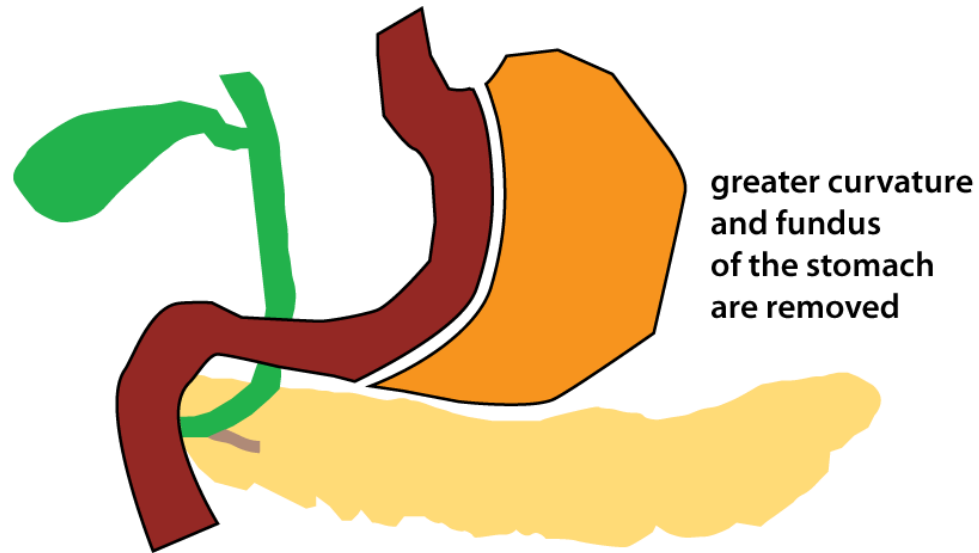
4. Name the structure indicated by the green arrow.

ileocecal valve



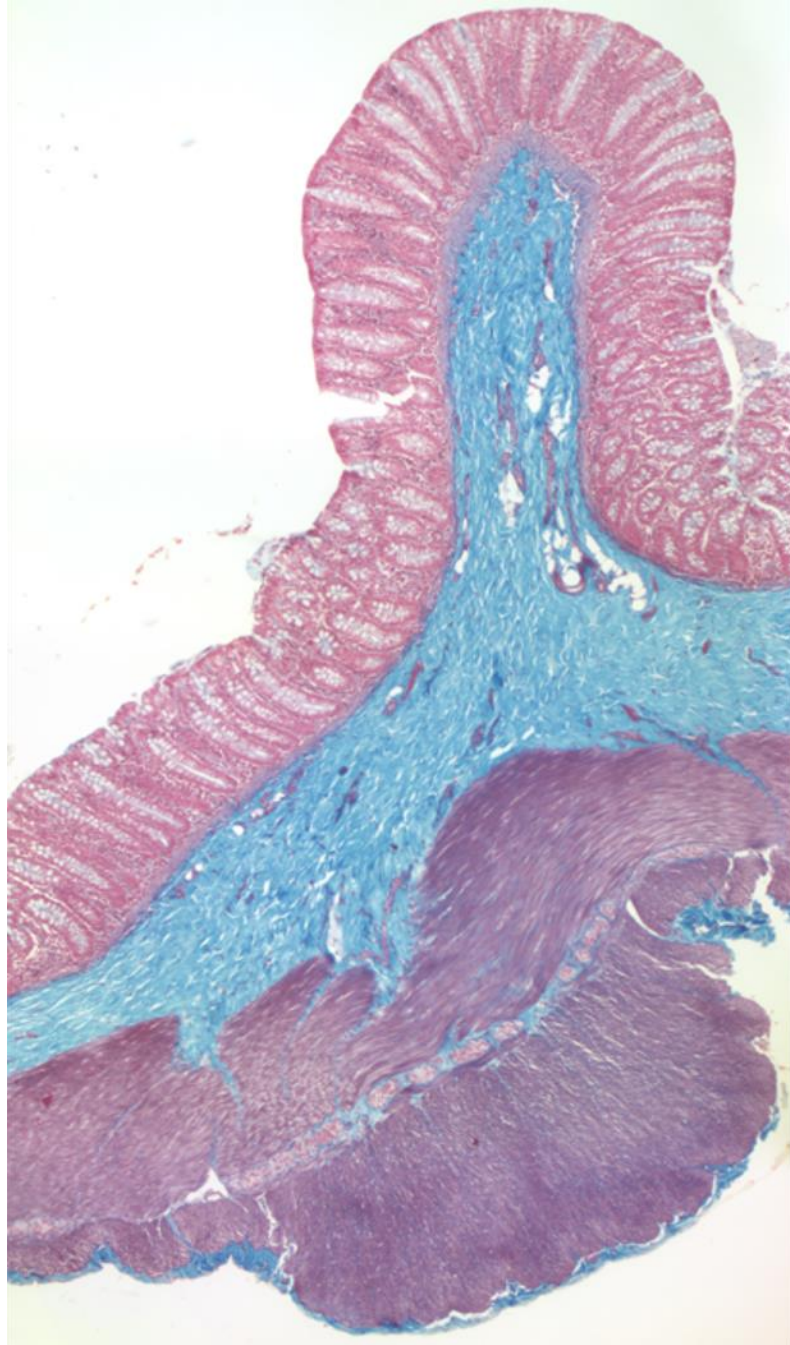
5. What region is indicated by the arrow?

- a. **antrum**
- b. body
- c. fundus
- d. pylorus



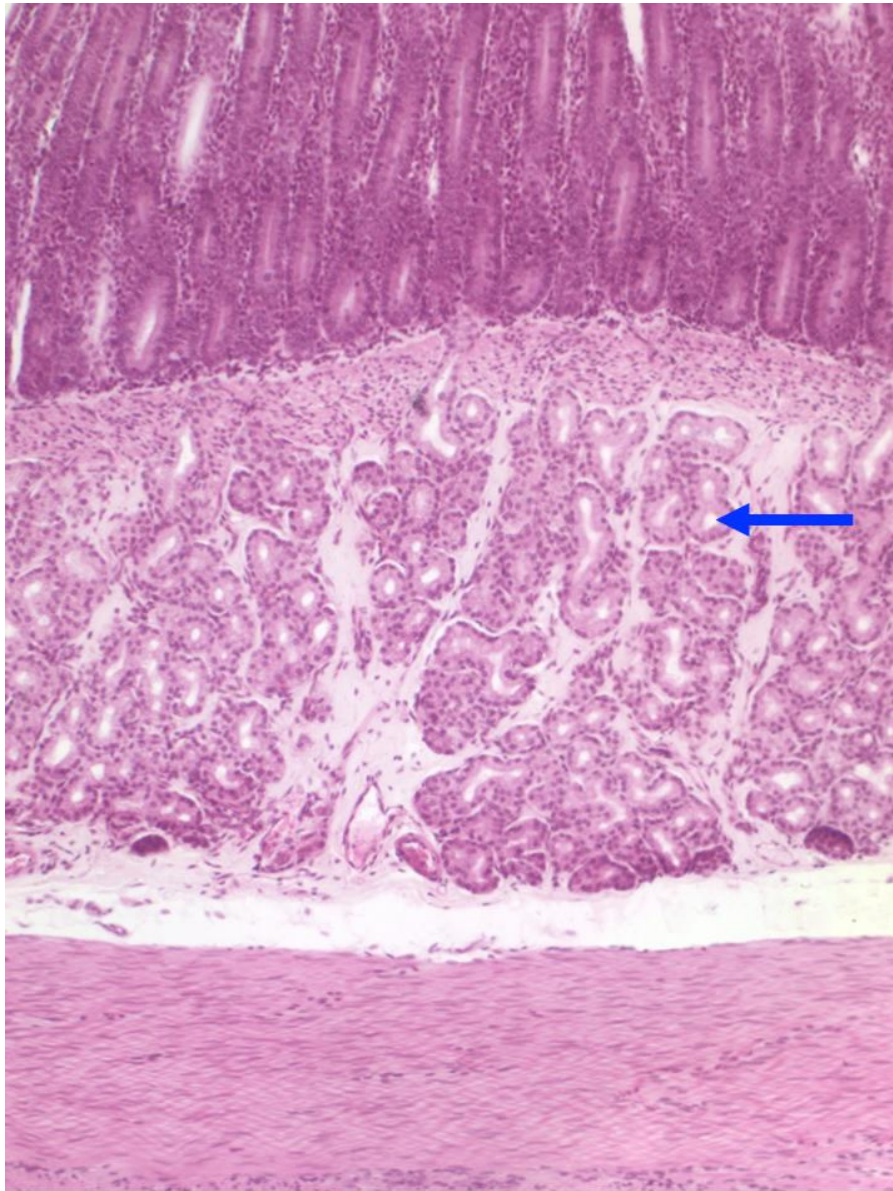
6. Fill in the blank. Decreased secretion of _____ occurs after sleeve gastrectomy, and may contribute to weight loss.

- a. GLP-1
- b. insulin
- c. mucus
- d. ghrelin
- e. PYY



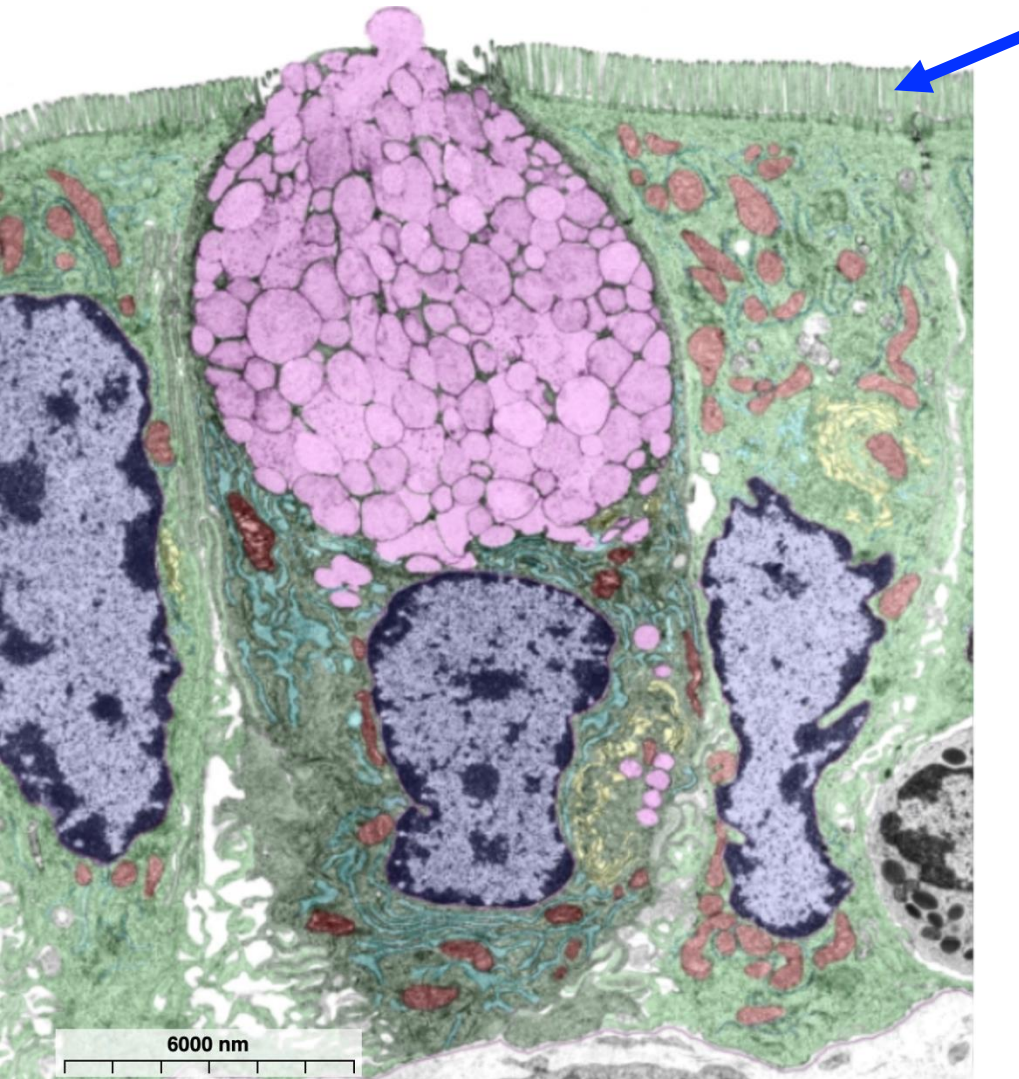
7. Which of the following organs is shown?

- a. esophagus
- b. stomach
- c. duodenum
- d. jejunum-ileum
- e. large intestine



8. Name the structure indicated by the arrow.

Brunner's gland

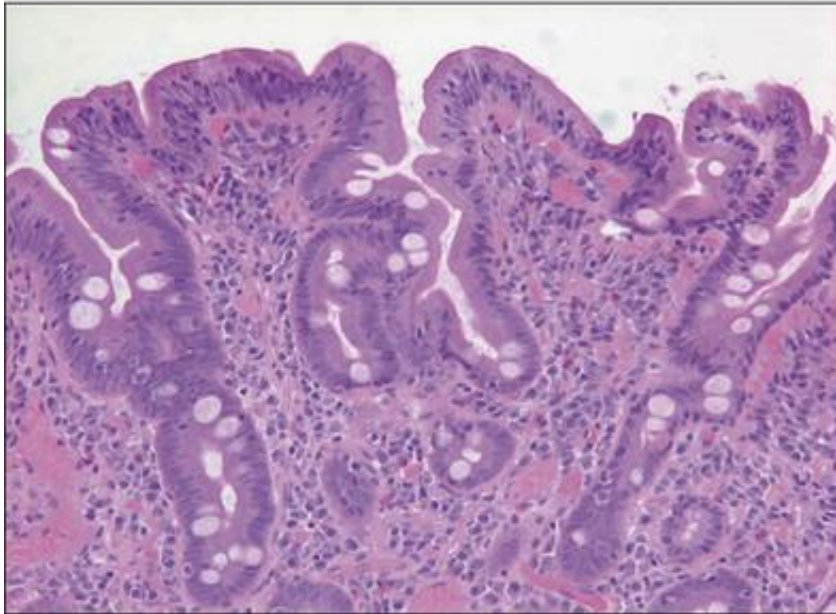


9. Name the structures indicated by the blue arrow.

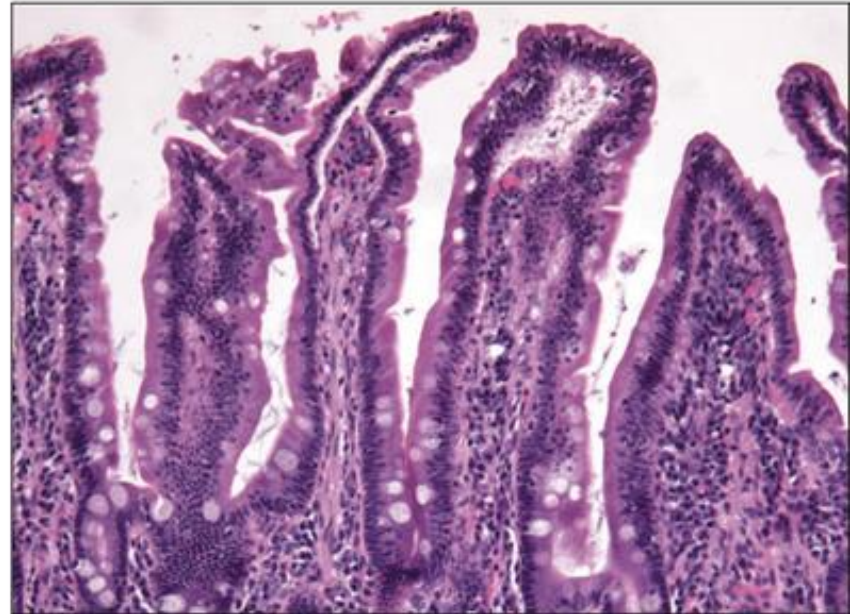
microvilli

A biopsy taken during her endoscopy showed **villous shortening** and an increased number of **intraepithelial lymphocytes**, consistent with **celiac disease**.

[A] Ms J's duodenal biopsy specimen



[B] Example of normal duodenal biopsy specimen



10. What was the other finding in this patient, consistent with the tissue damage that occurs in celiac disease?

- a. **anemia**
- b. increased hematocrit
- c. esophageal inflammation
- d. gastric ulcer