

# A Lack of Experience-Dependent Plasticity After More Than a Decade of Recovered Sight

Elizabeth Huber<sup>1</sup>, Jason M. Webster<sup>1</sup>, Alyssa A. Brewer<sup>2</sup>,  
 Donald I. A. MacLeod<sup>3</sup>, Brian A. Wandell<sup>4</sup>,  
 Geoffrey M. Boynton<sup>1</sup>, Alex R. Wade<sup>5</sup>, and Ione Fine<sup>1</sup>

<sup>1</sup>Department of Psychology, University of Washington; <sup>2</sup>Department of Cognitive Sciences, University of California, Irvine; <sup>3</sup>Department of Psychology, University of California, San Diego; <sup>4</sup>Department of Psychology, Stanford University; and <sup>5</sup>Department of Psychology, University of York

Psychological Science

1–9

© The Author(s) 2015

Reprints and permissions:

sagepub.com/journalsPermissions.nav

DOI: 10.1177/0956797614563957

pss.sagepub.com



## Abstract

In 2000, monocular vision was restored to M. M., who had been blind between the ages of 3 and 46 years. Tests carried out over 2 years following the surgery revealed impairments of 3-D form, object, and face processing and an absence of object- and face-selective blood-oxygen-level-dependent responses in ventral visual cortex. In the present research, we reexamined M. M. to test for experience-dependent recovery of visual function. Behaviorally, M. M. remains impaired in 3-D form, object, and face processing. Accordingly, we found little to no evidence of the category-selective organization within ventral visual cortex typically associated with face, body, scene, or object processing. We did observe remarkably normal object selectivity within lateral occipital cortex, consistent with M. M.'s previously reported shape-discrimination performance. Together, these findings provide little evidence for recovery of high-level visual function after more than a decade of visual experience in adulthood.

## Keywords

neuroimaging, vision, face perception, object recognition, temporal lobe

Received 2/13/14; Revision accepted 11/21/14

M. M. was 3.5 years old when a chemical explosion destroyed his left eye and caused severe corneal damage in his right. As described previously (Fine et al., 2003), M. M. had some perception of light but no experience of contrast or form over a period of 43 years. He reported no visual memories or imagery, despite one unsuccessful corneal replacement attempt in childhood. In 2000, M. M. received a corneal transplant and stem cell therapy, which restored vision in his remaining eye. In tests carried out over the first 2 years after surgery, M. M. showed severe amblyopia (an acuity limit of ~1.2 cycles per degree, corresponding to Snellen acuity of ~20/500) and substantial deficits in high-level visual processing (Fine et al., 2003).

Most cases of early visual deprivation are due to congenital cataracts that are diagnosed and removed within the first year of life. Thus, these cases differ substantially from that of M. M., who was blinded in early childhood

and remained blind for much of his adult life. Indeed, M. M.'s period of deprivation and the period found in more traditional examples of bilateral cataracts are practically nonoverlapping. Infants treated for congenital cataracts early in life regain useful visual function, though deficits in a variety of low-level (Maurer, Mondloch, & Lewis, 2007), mid-level (Ellemborg et al., 2005; Lewis et al., 2002), and high-level (Le Grand, Mondloch, Maurer, & Brent, 2004; Robbins, Nishimura, Mondloch, Lewis, & Maurer, 2010) capacities remain.

The period of visually driven normal development differs from both the sensitive period for damage and the sensitive period for recovery, and these developmental

## Corresponding Author:

Jason M. Webster, University of Washington, Department of Psychology, P. O. Box 351525, Seattle, WA 98195

E-mail: jwebst@uw.edu

windows differ substantially across various types of visual processing (Lewis & Maurer, 2005) and depend upon a complex balance between inhibitory and excitatory circuits that are themselves affected by deprivation (Bavelier, Levi, Li, Dan, & Hensch, 2010). At present, some uncertainty exists in the literature as to whether people whose sight is restored in adulthood can regain useful vision and over what timescale such improvement might occur. Previous studies and case reports (Cheselden, 1727; Fine et al., 2003; Gregory & Wallace, 1963; Šikl et al., 2013; Sinha & Held, 2012; Valvo, 1971) suggest that adults who have recovered their sight tend to find the visual world confusing and difficult to interpret even many months after surgery, although certain visual abilities seem to improve after surgery (Kalia et al., 2014; Ostrovsky, Meyers, Ganesh, Mathur, & Sinha, 2009), and some spared high-level visual function has been reported in one case of sight recovery in early adolescence (Ostrovsky, Andalman, & Sinha, 2006).

When tested shortly after surgery, M. M. had normal perception of color and motion, and only modest deficits in perception of simple form (Fine et al., 2003), consistent with the comparatively early sensitive periods proposed for these capacities. In contrast, M. M. showed severe deficits in many aspects of complex form, object, and face processing, accompanied by a lack of category-selective responses for faces or objects within ventral visual cortex, as measured using functional MRI (fMRI). Although these capacities are qualitatively present at 3 to 4 years of age, when M. M. lost vision, certain aspects of object and face processing continue to develop well into early childhood (Lewis & Maurer, 2005; McKone, Crookes, Jeffery, & Dilks, 2012; Nishimura, Scherf, & Behrmann, 2009), and the degree of plasticity within these areas after early childhood has not yet been established in humans. Thus, it remains possible that M. M. could have recovered these capacities with sufficient visual experience. In the work reported here, we used behavioral measures and fMRI to assess whether M. M.'s processing of complex form, objects, and faces has changed after more than 10 years of restored sight.

## Method

### *Subjects*

M. M. and 2 age- and gender-matched control subjects participated in both the behavioral and fMRI portions of the experiment. Two additional control subjects were excluded from the analysis because they fell asleep during the fMRI portion of the experiment. All procedures, including recruitment and testing, followed the guidelines of the University of Washington Human Subjects

Division and were approved by the institutional review board. All subjects provided informed consent.

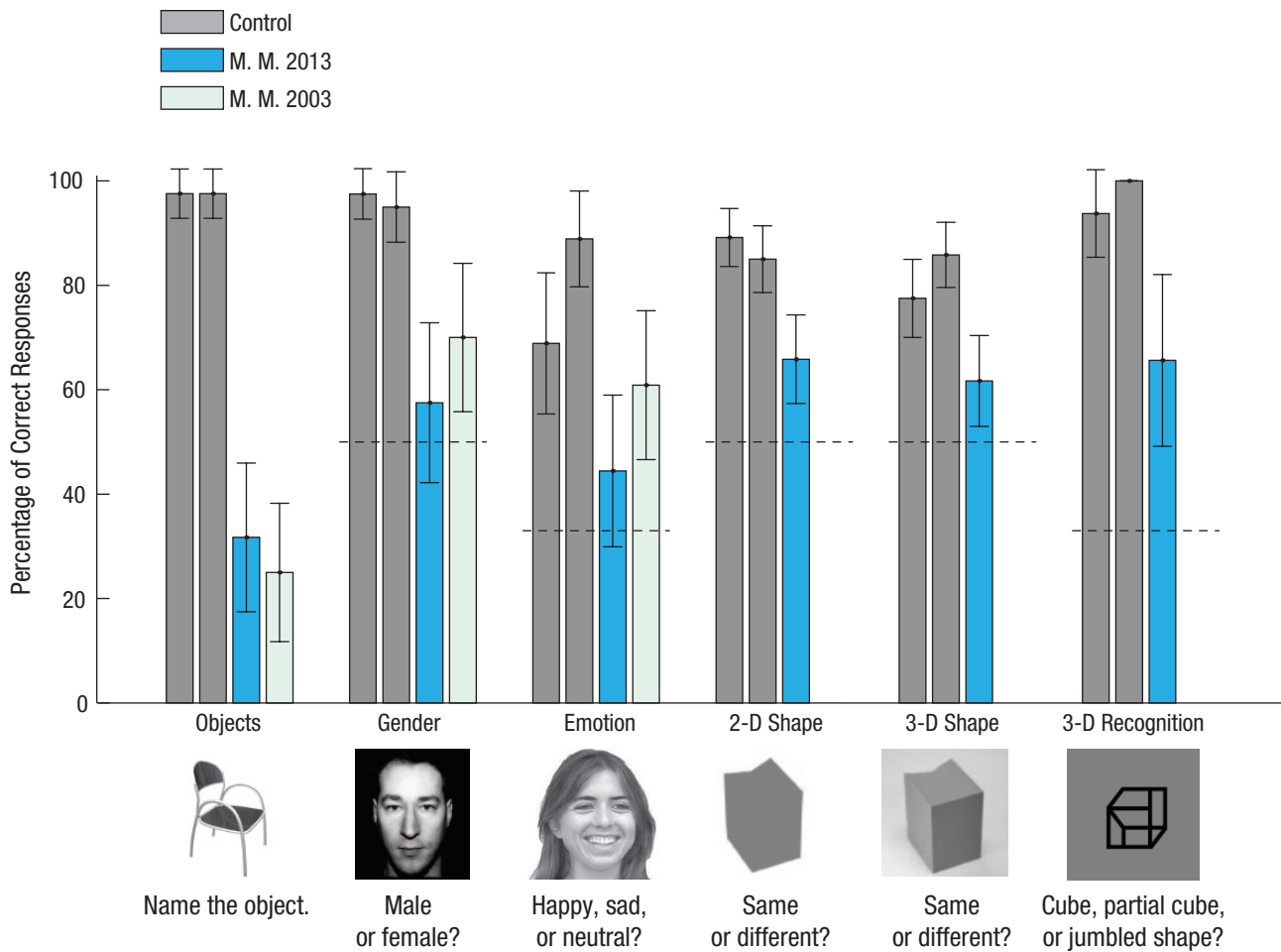
### *Procedure for behavioral experiments*

Because M. M. had studied the original object and face stimuli and received feedback after the previous experiments (Fine et al., 2003), different databases were used in the experiments described here to obtain novel but analogous stimuli. Object identification and emotion classification were tested using gray-scale images adapted from a standard stimulus set courtesy of Michael J. Tarr, Center for the Neural Basis of Cognition and Department of Psychology, Carnegie Mellon University (<http://www.tarlab.org/>). Gender classification was tested using stimuli adapted from the Stirling face set ([http://pics.stir.ac.uk/2D\\_face\\_sets.htm](http://pics.stir.ac.uk/2D_face_sets.htm)). To ensure that M. M. was familiar with the objects in our stimuli, we selected common household items to which he was regularly exposed. We chose novel face stimuli in which the number of non-configural cues, such as eyebrow shape and hair length, was minimized; M. M. had previously reported using such cues to discriminate male from female faces.

All stimuli were presented on a large flat-screen monitor, which subtended  $56 \times 42$  degrees of visual angle at a viewing distance of 35 cm. Stimulus images subtended roughly  $12^\circ$  and were presented in gray scale on plain, achromatic backgrounds. As in our original experiments (Fine et al., 2003), M. M. viewed unblurred stimuli, whereas control subjects viewed stimuli that were convolved with a Gaussian filter centered at 1 cycle per degree to match M. M.'s psychophysically determined acuity (see Fig. S1 and Contrast Sensitivity Function in the Supplemental Material available online). M. M.'s acuity has remained stable since the initial tests conducted shortly after he recovered his sight (Fine et al., 2003; Levin, Dumoulin, Winawer, Dougherty, & Wandell, 2010). We chose the number of trials to run per task prior to the start of data collection to allow presentation of several exemplars from each category while minimizing fatigue in M. M., for whom the tasks were challenging.

To assess perception of complex 3-D form, we presented subjects with line drawings of cubes that were intact, had a single line missing, or were rearranged to disrupt the 3-D structure while preserving local junctions. Subjects completed 32 trials in total. On each trial, a stimulus was presented for 4 s, followed by an unlimited response interval. Subjects were asked to report via key press whether each image depicted a cube or a jumbled shape.

To further test perception of simple shape and 3-D form, we adapted a set of stimuli containing images of 3-D forms photographed from various viewpoints spanning a  $360^\circ$  rotation (Scharff, Palmer, & Moore, 2013). To



**Fig. 1.** Mean percentage of correct responses as a function of stimulus category. Results are shown separately for each control subject, for M. M. in 2013, and for M. M. in 2003. An example unblurred stimulus image is shown for each category; however, in this experiment, all stimuli shown to control subjects were blurred to match M. M.'s visual-acuity losses. Where applicable, chance performance is indicated with a dashed line. Error bars represent 95% confidence intervals.

create a version of the task that did not require interpolation in depth, we modified a subset of the stimuli by tracing their outer contours and then filling them with a uniform gray (see Fig. 1 for example stimulus images). Subjects matched 3-D images across rotations in depth and 2-D images across rotations in the  $x$ - $y$  plane. There were 60 trials in each condition. Stimuli remained on-screen until subjects pressed one of two keys to report whether two images, shown simultaneously on the left and right halves of the display, contained rotated versions of the same object or different objects. All subjects completed the 2-D version of the task first.

For the object-identification task, subjects were asked to verbally identify each of 41 unique items, advancing to the next trial by pressing a key when they were unsure of an object's identity. Gender (male, female) and emotion (happy, neutral, sad) classification were tested via two- and three-alternative forced-choice paradigms,

respectively. The gender-classification task consisted of 40 trials (20 faces of each gender) and the emotion-classification task consisted of 45 trials (15 individuals displaying each emotional expression). As with the shape stimuli, face and object stimuli were presented individually for 4 s at the center of the display, and subjects had unlimited time to respond by pressing a key.

### ***Procedure for fMRI experiment***

Category-selective regions in the ventral visual pathway have been well characterized in subjects who have normal sight (Kanwisher & Dilks, 2013). To ensure that any absence of this organization in M. M. could not be attributed to his reduced acuity, we showed control subjects blurred as well as unblurred versions of the stimuli.

Subjects viewed stimuli presented on a screen at the end of the scanner bore via a mirror attached to the

head coil. Cortical category-selective blood-oxygen-level-dependent (BOLD) responses were estimated using freely viewed, colorful, full-screen 3-s video clips presented using a block design that alternated between faces, bodies, scenes, objects, and scrambled objects (Julian, Fedorenko, Webster, & Kanwisher, 2012). Face, body, and object videos were recorded against a black background. Scene stimuli consisted mostly of rural locations and included buildings, yards, and forested roads. To create scrambled versions of the object stimuli, we segmented each object clip into a  $15 \times 15$  grid, and spatial locations were shuffled in a pseudorandom order. Example frames are shown in Figure S2 in the Supplemental Material.

Each block lasted 18 s and consisted of six clips. Uniformly colored screens were used as a baseline and were presented at the beginning, middle, and end of each run. The blocks of movie clips in each run were presented in a palindromic order (e.g., one order used was cFSOBGcGBOSFc, where F = faces, B = bodies, S = scenes, O = objects, G = grid-scrambled objects, and c = uniformly colored screens). Each subject completed eight 234-s runs. Control subjects first completed four runs with an eye patch over the left eye. In these runs, the stimuli were blurred with a Gaussian filter to match M. M.'s psychophysically determined acuity. In the following four runs, control subjects binocularly viewed unblurred stimuli, which allowed us to directly assess the effects of blurring and monocular viewing on category-selective organization. M. M. always viewed unblurred stimuli with his remaining (right) eye.

Scanning was performed using a 3-T Allegra scanner with a 32-channel head coil at the Diagnostic Imaging Sciences Center at the University of Washington. High-resolution T1-weighted magnetization-prepared rapid-acquisition gradient-echo images were collected in 128 sagittal slices (repetition time, or TR = 7.6 ms, echo time, or TE = 3.5 ms, voxel size = 1 mm isotropic). BOLD images were acquired with a gradient-echo echo-planar image sequence (TR = 1,500 ms, TE = 25 ms, flip angle =  $75^\circ$ , field of view =  $220 \times 220$ , voxel size = 3 mm isotropic). The acquisition window was positioned off axial to include the temporal and occipital lobes.

Structural MRI data were analyzed with FreeSurfer (Version 5.2; <http://surfer.nmr.mgh.harvard.edu/>) to construct cortical surface models for each subject. FsFast (Version 5.2; <https://surfer.nmr.mgh.harvard.edu/fswiki/FsFast>) was used to process fMRI data. Preprocessing involved motion correction using the 3dvolreg algorithm in the Analysis of Functional and Neural Images (AFNI) software suite (Cox & Jesmanowicz, 1999) and the FMRIB Software Library Brain Extraction Tool (Smith, 2002). Each functional run was then registered to that subject's cortical surface model using boundary-based registration (Greve & Fischl, 2009). A general linear model was used

to estimate the cortical response to each experimental condition. Statistical contrasts were computed for faces and objects, objects and scrambled objects, bodies and objects, and scenes and objects. Contrast maps were assessed at a threshold of  $|p| < .0001$ , uncorrected, prior to further analyses, as in numerous previous studies of the ventral visual stream (Downing, Jiang, Shuman, & Kanwisher, 2001; Epstein & Kanwisher, 1998; Kanwisher & Dilks, 2013; Kanwisher, McDermott, & Chun, 1997; Malach et al., 1995). Data were not smoothed or normalized to a template.

## Results

### *Behavioral experiments*

M. M. discriminated images of cubes from incomplete and scrambled versions with accuracy greater than chance level, but his performance was significantly below that of control subjects, which suggests that M. M. remains impaired in 3-D form perception. Similarly, M. M.'s performance on a simple 2-D rotation task was higher than expected from chance alone, but significantly worse than control subjects' performance. When required to match 3-D forms at varying rotations in depth, M. M.'s performance was indistinguishable from chance and significantly below that of control subjects. M. M. correctly named several household objects, though significantly fewer than did control subjects, for whom the task was trivial. For both the gender- and emotion-classification tasks, M. M.'s performance was significantly worse than that of control subjects and not distinguishable from chance. Finally, M. M. showed no significant improvement in performance between 2003 and 2013 for any of the tasks. See Table 1 and Figure 1 for a summary of these results.

### *fMRI experiments*

Control subjects' responses to monocularly viewed, blurred stimuli and binocularly viewed, unblurred stimuli were qualitatively similar (data for the latter are not reported).

**Face and object selectivity.** Consistent with previous research (for a review, see Kanwisher & Dilks, 2013), our results showed that control subjects had robust category-selective responses for faces and objects within lateral occipital and ventral temporal cortex. Figures 2a and 2b show data from 1 control subject (four runs with blurred, monocularly viewed stimuli; data from the other control subject are in Fig. S7 in the Supplemental Material). As expected, a contrast between faces and objects (Fig. 2a) isolated face-selective regions in the lateral occipital



**Table 1.** M. M.'s Performance in the Six Behavioral Tasks Compared With Chance, Control Subjects' Performance, and M. M.'s Prior Performance

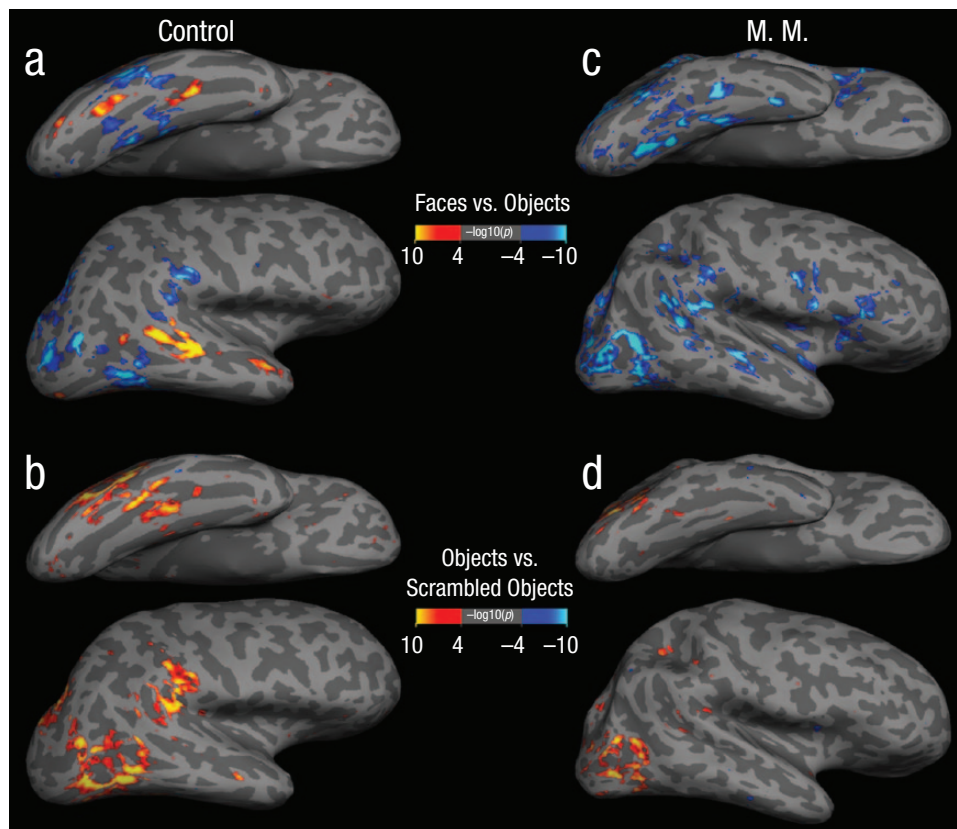
Comparison	Object recognition	Face classification: gender	Face classification: emotion	2-D shape constancy	3-D shape constancy	3-D shape recognition
M. M. vs. chance	—	.075 [-.14, .29]	.11 [-.085, .31]	.16* [.035, .28]	.12 [-.0081, .24]	.33** [.095, .56]
M. M. vs. control subjects	-.66** [-.81, -.51]	-.43** [-.58, -.27]	-.34** [-.53, -.16]	-.21** [-.32, -.11]	-.20** [-.31, -.088]	-.31** [-.49, -.14]
M. M. 2013 vs. M. M. 2003	.067 [-.15, .28]	-.13 [-.35, .099]	-.16 [-.41, .082]	—	—	—

Note: The table presents the difference in the proportion of correct responses and the corresponding 95% confidence intervals. \* $p < .05$ . \*\* $p < .01$ .

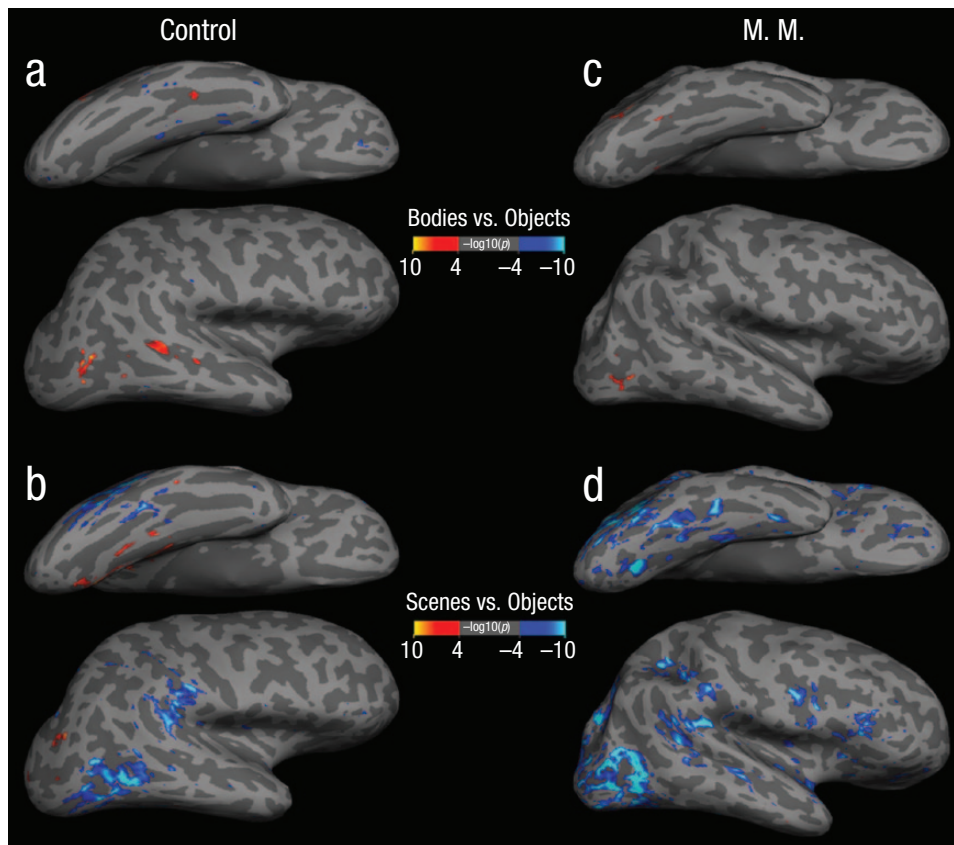
cortex (LOC), superior temporal sulcus, and fusiform gyrus in both control subjects. Similarly, a contrast between objects and scrambled objects revealed a typical pattern of object-selective regions (Fig. 2b).

In contrast, M. M. showed no evidence of face selectivity, even after more than a decade of recovered sight (Fig. 2c). While some regions in ventral temporal cortex responded more to objects than to faces, these regions

did not show a selective response to objects in a contrast between objects and scrambled objects (Fig. 2d), which suggests that M. M. also lacks typical high-level object-selective cortical responses. With a very lenient threshold, there was some evidence for a highly attenuated object-selective response in the ventral temporal cortex, though this potential activity was not clearly differentiable from noise (see Fig. S5 in the Supplemental Material).



**Fig. 2.** Ventral and lateral views of inflated right hemispheres showing results of the contrasts between faces and objects (a, c) and between objects and scrambled objects (b, d). Results are shown separately for 1 control subject (left column) and for M. M. (right column). Data were averaged across four scans (in which stimuli were blurred and monocularly viewed) for the control subject and eight scans for M. M. Results are displayed at a threshold of  $|p| < .0001$ . (See Fig. S3 in the Supplemental Material for left-hemisphere activations in response to the same contrasts.)



**Fig. 3.** Ventral and lateral views of inflated right hemispheres showing results of the contrasts between bodies and objects (a, c) and between scenes and objects (b, d). Results are shown separately for 1 control subject (left column) and for M. M. (right column). Data were averaged across four scans (in which stimuli were blurred and monocularly viewed) for the control subject and eight scans for M. M. Results are displayed at a threshold of  $|p| < .0001$ . (See Fig. S4 in the Supplemental Material for left-hemisphere activations in response to the same contrasts.)

M. M. did show object-selective activity in the contrast of objects versus scrambled objects on the lateral surface in a location consistent with the object-selective region LOC. Given that M. M. has no difficulty discriminating different 2-D shapes (Fine et al., 2003), this finding is compatible with those of previous studies suggesting that LOC encodes shapes without being involved with matching those shapes to stored object representations (Grill-Spector et al., 1999; Kanwisher & Dilks, 2013; Kourtzi & Kanwisher, 2001; Malach et al., 1995), though we caution that our finding of relatively intact responses in LOC should not be taken as evidence for fully functional shape encoding.

**Scene selectivity.** The contrast of scenes versus objects did not yield the expected results in our control subjects. Monocular viewing of blurred stimuli produced attenuated responses in the right parahippocampal cortex of 1 subject (Fig. 3b), although this subject had a robust response in the left hemisphere (see Fig. S4b in the

Supplemental Material). In a second control subject, we found very little scene-selective response for the blurred stimuli (see Figs. S8b and S8d in the Supplemental Material). Both of these subjects showed typical responses to unblurred stimuli. It is possible that the lack of scene-selective response, particularly in the parahippocampal place area, results from a high-spatial-frequency bias in this region (Rajimehr, Devaney, Bilenko, Young, & Tootell, 2011). M. M. showed no scene-selective responses in either the lateral occipital or ventral temporal cortex (Fig. 3d) in either hemisphere (see also Fig. S4d in the Supplemental Material). At a lower threshold, we observed a small region consistent with the parahippocampal place area that responded slightly more to scenes than to objects, though this potential activity was not clearly differentiable from noise (see Figs. S6b and S6d in the Supplemental Material).

**Body selectivity.** In control subjects, body-selective responses were evident in the lateral occipital and ventral

temporal cortex (Fig. 3a) in both hemispheres (see Fig. S4a in the Supplemental Material; for the body-selective responses in the other control subject, see Figs. S8a and S8c). While we saw little evidence of the typical ventral temporal responses to bodies at a conventional threshold in M. M., we did observe body-selective responses in a region consistent with the extrastriate body area within the right hemisphere (Fig. 3c). There were no corresponding body-selective responses in the left hemisphere (see Fig. S4c in the Supplemental Material). With a very lenient threshold, we did observe a region in a location consistent with the fusiform body area responding more strongly to bodies than to objects (see Figs. S6a and S6c in the Supplemental Material), though these responses were again not clearly differentiable from noise.

## Discussion

Visual function continues to develop throughout childhood and into early adolescence, with performance on tasks such as object recognition and face processing reaching adultlike levels between the ages of 5 to 8 and 4 to 6 years, respectively, while remaining sensitive to deprivation for several years afterward (McKone et al., 2012; Nishimura et al., 2009). Subject M. M.'s vision developed normally up to 3.5 years of age, after which he experienced an extended period of visual deprivation until his sight was restored well after adolescence. Thus, his case provides a unique opportunity to assess both the limits of plasticity in later adulthood and the influence of early vision on recovery from long-term blindness.

Tests carried out with M. M. shortly after surgery suggested that he had normal perception of color and motion, and only modest deficits in perception of simple form. M. M. shows essentially normal cortical responses to visual-motion stimuli (Fine et al., 2003), consistent with his behavioral sensitivity to motion cues, though these responses seem to coexist with auditory-motion responses not present in sighted individuals (Saenz, Lewis, Huth, Fine, & Koch, 2008). Consistent with M. M.'s ability to interpret simple 2-D forms, described first by Fine et al. (2003) and examined further here, our present results show relatively normal responses in the cortical region known as LOC, which has been implicated in the processing of object shape (Grill-Spector et al., 1999). One possibility is that spared perception of color, motion, and shape reflects hard wiring of these faculties; indeed, evidence suggests that this may be the case with basic color processing (Mancuso et al., 2009). Alternatively, preservation of these faculties may indicate that their periods of sensitivity to deprivation end prior to 3.5 years of age.

Several recent studies have suggested that cross-modal responses resulting from early blindness may follow an

organization that is analogous to that of at least some high-level visual areas in normally sighted individuals. For instance, cortical regions typically associated with visual object processing have been implicated in object-size estimation in the congenitally blind (Mahon, Anzellotti, Schwarzbach, Zampini, & Caramazza, 2009), and these regions contain information about similarities in object shape in both sighted and blind participants (Peelen, He, Han, Caramazza, & Bi, 2014). Activity has also been reported in the visual word form area during Braille reading (Buchel, Price, & Friston, 1998; Reich, Szwed, Cohen, & Amedi, 2011), and the emergence of body-selective regions in congenitally blind subjects has been reported as a result of training with soundscapes representing bodies (Striem-Amit & Amedi, 2014). Similarly, activation of common regions during visual and haptic recognition of facial expressions in sighted and blind subjects (Kitada et al., 2013) suggests that haptic experience may be sufficient for development of these regions in the absence of visual input.

Although M. M. had normal sight until 3.5 years of age, the literature suggests that this is well within the period when some forms of cross-modal plasticity occur (e.g., Burton et al., 2002; Gougoux et al., 2009; Sadato, Okada, Honda, & Yonekura, 2002), and he shows robust cross-modal responses to auditory-motion stimuli (Saenz et al., 2008). However, we do not know the extent of cortical cross-modal responses in M. M. beyond these auditory-motion responses in cortical visual motion areas. Further, it is unclear whether any existing cross-modal responses would facilitate or interfere with restored visual function. As described previously, M. M. has essentially normal perception of visual motion, and his cortical responses to both visual and auditory motion are robust. In contrast, despite several years of early visual experience and more than a decade of recovered sight, M. M. remains profoundly impaired at interpreting visual facial expressions, which suggests that his haptic experience with faces and voice perception (Gougoux et al., 2009) did not lead to the preservation of neural architecture relevant for visual face recognition. Similarly, although we did observe relatively normal selectivity for bodies and objects within LOC, we found little to no evidence of high-level visual responses in ventral temporal cortex selective for face, body, scene, or object stimuli in M. M.

Shortly after recovering his sight, M. M. showed severe behavioral deficits in high-level visual tasks, and our follow-up tests revealed these to be long-standing impairments. When asked what challenges to vision remained in his daily life, M. M. replied, "I have learned what works with vision and what doesn't, so I really don't challenge my vision much anymore." M. M. now uses a combination of vision and other modalities for specific tasks. "This means where motion or color might be clues, I use my

vision. Where details might be required, like reading print or recognizing who someone is, I use tactile and auditory techniques.”

In conclusion, M. M. continues to show severe behavioral impairments in 3-D form, object, and face processing with no evidence of improvement of recognition performance even after more than a decade of recovered vision. These behavioral impairments are associated with highly attenuated category-selective activity in ventral visual cortex, which suggests that adult high-level vision is based on a visual architecture that is still sensitive to deprivation at the age of 3 years and that has only limited plasticity in adulthood.

### Author Contributions

E. Huber and J. M. Webster share first authorship of this article. E. Huber, J. M. Webster, and I. Fine designed the research. J. M. Webster and E. Huber collected and analyzed the data. E. Huber, J. M. Webster, and I. Fine drafted the manuscript. All authors provided critical revisions and approved the final draft of the manuscript.

### Acknowledgments

We thank Shirley-Ann Rueschemeyer, Claudia Williams, Elise Grimm, Eva Wilmots, Samantha Harris, and Tiril Wilhelmsen for useful comments and suggestions.

### Declaration of Conflicting Interests

The authors declared that they had no conflicts of interest with respect to their authorship or the publication of this article.

### Funding

This work was supported by National Institutes of Health Grant No. R01EY-014645 from the National Eye Institute.

### Supplemental Material

Additional supporting information can be found at <http://pss.sagepub.com/content/by/supplemental-data>

### References

- Bavelier, D., Levi, D. M., Li, R. W., Dan, Y., & Hensch, T. K. (2010). Removing brakes on adult brain plasticity: From molecular to behavioral interventions. *Journal of Neuroscience*, *30*, 14964–14971. doi:10.1523/JNEUROSCI.4812-10.2010
- Buchel, C., Price, C., & Friston, K. (1998). A multimodal language region in the ventral visual pathway. *Nature*, *394*, 274–277. doi:10.1038/28389
- Burton, H., Snyder, A. Z., Conturo, T. E., Akbudak, E., Ollinger, J. M., & Raichle, M. E. (2002). Adaptive changes in early and late blind: A fMRI study of Braille reading. *Journal of Neurophysiology*, *87*, 589–607.
- Cheselden, W. (1727). An account of some observations made by a young gentleman, who was born blind, or lost his sight so early, that he had no remembrance of ever having seen, and was couch'd between 13 and 14 years of age. *Philosophical Transactions*, *35*, 447–450. doi:10.1098/rstl.1727.0038
- Cox, R. W., & Jesmanowicz, A. (1999). Real-time 3D image registration for functional MRI. *Magnetic Resonance in Medicine*, *42*, 1014–1018.
- Downing, P. E., Jiang, Y., Shuman, M., & Kanwisher, N. (2001). A cortical area selective for visual processing of the human body. *Science*, *293*, 2470–2473. doi:10.1126/science.1063414
- Ellemberg, D., Lewis, T. L., Defina, N., Maurer, D., Brent, H. P., Guillemot, J. P., & Lepore, F. (2005). Greater losses in sensitivity to second-order local motion than to first-order local motion after early visual deprivation in humans. *Vision Research*, *45*, 2877–2884. doi:10.1016/j.visres.2004.11.019
- Epstein, R., & Kanwisher, N. (1998). A cortical representation of the local visual environment. *Nature*, *392*, 598–601. doi:10.1038/33402
- Fine, I., Wade, A. R., Brewer, A. A., May, M. G., Goodman, D. F., Boynton, G. M., . . . MacLeod, D. I. A. (2003). Long-term deprivation affects visual perception and cortex. *Nature Neuroscience*, *6*, 915–916. doi:10.1038/nn1102
- Gougoux, F., Belin, P., Voss, P., Lepore, F., Lassonde, M., & Zatorre, R. J. (2009). Voice perception in blind persons: A functional magnetic resonance imaging study. *Neuropsychologia*, *47*, 2967–2974. doi:10.1016/j.neuropsychologia.2009.06.027
- Gregory, R. L., & Wallace, J. G. (1963). *Recovery from early blindness: A case study*. Retrieved from [http://www.richardgregory.org/papers/recovery\\_blind/recovery-from-early-blindness.pdf](http://www.richardgregory.org/papers/recovery_blind/recovery-from-early-blindness.pdf)
- Greve, D. N., & Fischl, B. (2009). Accurate and robust brain image alignment using boundary-based registration. *NeuroImage*, *48*, 63–72. doi:10.1016/j.neuroimage.2009.06.060
- Grill-Spector, K., Kushnir, T., Edelman, S., Avidan, G., Itzhak, Y., & Malach, R. (1999). Differential processing of objects under various viewing conditions in the human lateral occipital complex. *Neuron*, *24*, 187–203.
- Julian, J. B., Fedorenko, E., Webster, J., & Kanwisher, N. (2012). An algorithmic method for functionally defining regions of interest in the ventral visual pathway. *NeuroImage*, *60*, 2357–2364. doi:10.1016/j.neuroimage.2012.02.055
- Kalia, A., Lesmes, L. A., Dorr, M., Gandhi, T., Chatterjee, G., Ganesh, S., . . . Sinha, P. (2014). Development of pattern vision following early and extended blindness. *Proceedings of the National Academy of Sciences, USA*, *111*, 2035–2039. doi:10.1073/pnas.1311041111
- Kanwisher, N., & Dilks, D. D. (2013). The functional organization of the ventral visual pathway in humans. In J. S. Werner & L. M. Chalupa (Eds.), *The new visual neurosciences* (pp. 733–748). Cambridge, MA: MIT Press.
- Kanwisher, N., McDermott, J., & Chun, M. M. (1997). The fusiform face area: A module in human extrastriate cortex specialized for face perception. *Journal of Neuroscience*, *17*, 4302–4311.
- Kitada, R., Okamoto, Y., Sasaki, A. T., Kochiyama, T., Miyahara, M., Lederman, S. J., & Sadato, N. (2013). Early visual experience and the recognition of basic facial expressions: Involvement of the middle temporal and inferior frontal gyri during haptic identification by the early blind. *Frontiers*



- in *Human Neuroscience*, 7, Article 7. Retrieved from <http://journal.frontiersin.org/Journal/10.3389/fnhum.2013.00007/full>
- Kourtzi, Z., & Kanwisher, N. (2001). Representation of perceived object shape by the human lateral occipital complex. *Science*, 293, 1506–1509. doi:10.1126/science.1061133
- Le Grand, R., Mondloch, C. J., Maurer, D., & Brent, H. P. (2004). Impairment in holistic face processing following early visual deprivation. *Psychological Science*, 15, 762–768. doi:10.1111/j.0956-7976.2004.00753.x
- Levin, N., Dumoulin, S. O., Winawer, J., Dougherty, R. F., & Wandell, B. A. (2010). Cortical maps and white matter tracts following long period of visual deprivation and retinal image restoration. *Neuron*, 65, 21–31. doi:10.1016/j.neuron.2009.12.006
- Lewis, T. L., Ellemberg, D., Maurer, D., Wilkinson, F., Wilson, H. R., Dirks, M., & Brent, H. P. (2002). Sensitivity to global form in glass patterns after early visual deprivation in humans. *Vision Research*, 42, 939–948.
- Lewis, T. L., & Maurer, D. (2005). Multiple sensitive periods in human visual development: Evidence from visually deprived children. *Developmental Psychobiology*, 46, 163–183. doi:10.1002/dev.20055
- Mahon, B. Z., Anzellotti, S., Schwarzbach, J., Zampini, M., & Caramazza, A. (2009). Category-specific organization in the human brain does not require visual experience. *Neuron*, 63, 397–405. doi:10.1016/j.neuron.2009.07.012
- Malach, R., Reppas, J. B., Benson, R. R., Kwong, K. K., Jiang, H., Kennedy, W. A., . . . Tootell, R. B. (1995). Object-related activity revealed by functional magnetic resonance imaging in human occipital cortex. *Proceedings of the National Academy of Sciences, USA*, 92, 8135–8139.
- Mancuso, K., Hauswirth, W. W., Li, Q., Connor, T. B., Kuchenbecker, J. A., Mauck, M. C., . . . Neitz, M. (2009). Gene therapy for red-green colour blindness in adult primates. *Nature*, 461, 784–787. doi:10.1038/nature08401
- Maurer, D., Mondloch, C. J., & Lewis, T. L. (2007). Effects of early visual deprivation on perceptual and cognitive development. *Progress in Brain Research*, 164, 87–104. doi:10.1016/S0079-6123(07)64005-9
- McKone, E., Crookes, K., Jeffery, L., & Dilks, D. D. (2012). A critical review of the development of face recognition: Experience is less important than previously believed. *Cognitive Neuropsychology*, 29, 174–212. doi:10.1080/02643294.2012.660138
- Nishimura, M., Scherf, S., & Behrmann, M. (2009). Development of object recognition in humans. *F1000 Biology Reports*, 1, 56. doi:10.3410/B1-56
- Ostrovsky, Y., Andalman, A., & Sinha, P. (2006). Vision following extended congenital blindness. *Psychological Science*, 17, 1009–1014. doi:10.1111/j.1467-9280.2006.01827.x
- Ostrovsky, Y., Meyers, E., Ganesh, S., Mathur, U., & Sinha, P. (2009). Visual parsing after recovery from blindness. *Psychological Science*, 20, 1484–1491. doi:10.1111/j.1467-9280.2009.02471.x
- Peelen, M. V., He, C., Han, Z., Caramazza, A., & Bi, Y. (2014). Nonvisual and visual object shape representations in occipitotemporal cortex: Evidence from congenitally blind and sighted adults. *Journal of Neuroscience*, 34, 163–170. doi:10.1523/JNEUROSCI.1114-13.2014
- Rajimehr, R., Devaney, K. J., Bilenko, N. Y., Young, J. C., & Tootell, R. B. (2011). The “parahippocampal place area” responds preferentially to high spatial frequencies in humans and monkeys. *PLoS Biology*, 9(4), Article e1000608. Retrieved from <http://www.plosbiology.org/article/info%3Adoi%2F10.1371%2Fjournal.pbio.1000608>
- Reich, L., Szwed, M., Cohen, L., & Amedi, A. (2011). A ventral visual stream reading center independent of visual experience. *Current Biology*, 21, 363–368. doi:10.1016/j.cub.2011.01.040
- Robbins, R. A., Nishimura, M., Mondloch, C. J., Lewis, T. L., & Maurer, D. (2010). Deficits in sensitivity to spacing after early visual deprivation in humans: A comparison of human faces, monkey faces, and houses. *Developmental Psychobiology*, 52, 775–781. doi:10.1002/dev.20473
- Sadato, N., Okada, T., Honda, M., & Yonekura, Y. (2002). Critical period for cross-modal plasticity in blind humans: A functional MRI study. *NeuroImage*, 16, 389–400.
- Saenz, M., Lewis, L. B., Huth, A. G., Fine, I., & Koch, C. (2008). Visual motion area MT+/V5 responds to auditory motion in human sight-recovery subjects. *Journal of Neuroscience*, 28, 5141–5148. doi:10.1523/JNEUROSCI.0803-08.2008
- Scharff, A., Palmer, J., & Moore, C. M. (2013). Divided attention limits perception of 3-D object shapes. *Journal of Vision*, 13(2), Article 18. Retrieved from <http://www.journalofvision.org/content/13/2/18.full>
- Šikl, R., Šimeček, M., Porubanová-Norquist, M., Bezdíček, O., Kremláček, J., Stodůlka, P., . . . Ostrovsky, Y. (2013). Vision after 53 years of blindness. *i-Perception*, 4, 498–507.
- Sinha, P., & Held, R. (2012). Sight restoration. *F1000 Medicine Reports*, 4, 17. doi:10.3410/M4-17
- Smith, S. M. (2002). Fast robust automated brain extraction. *Human Brain Mapping*, 17, 143–155. doi:10.1002/hbm.10062
- Striemi-Amit, E., & Amedi, A. (2014). Visual cortex extrastriate body-selective area activation in congenitally blind people “seeing” by using sounds. *Current Biology*, 24, 687–692. doi:10.1016/j.cub.2014.02.010
- Valvo, A. (1971). *Sight restoration after long-term blindness: The problems and behavior patterns of visual rehabilitation*. New York, NY: American Foundation for the Blind.